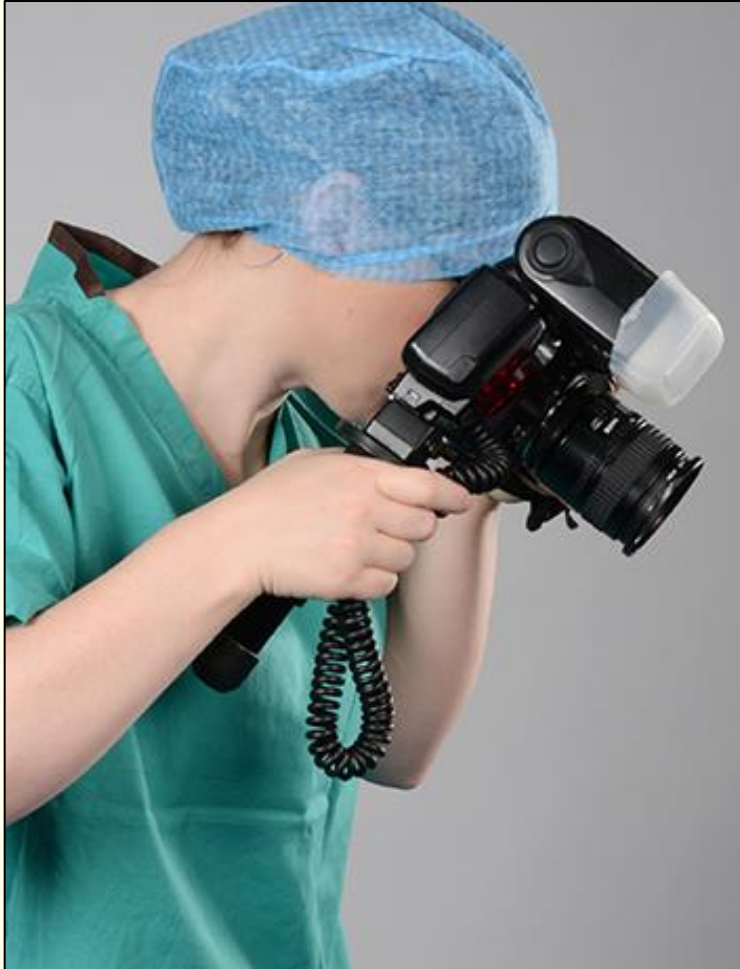



Photography in Veterinary Medicine

Dr Esther van Praag

2016 - Photo Club CERN

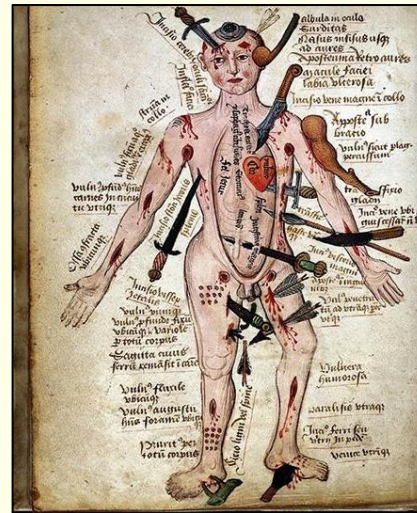
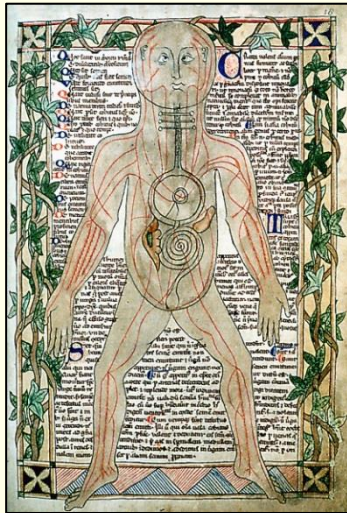


A common error is to think of medical photography as just one new specialty among many.

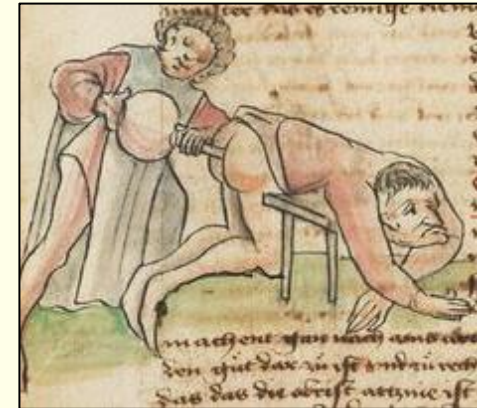Medical illustration is as old as medicine itself !!!

Medieval illustrations of
Wounds in man

Veins system

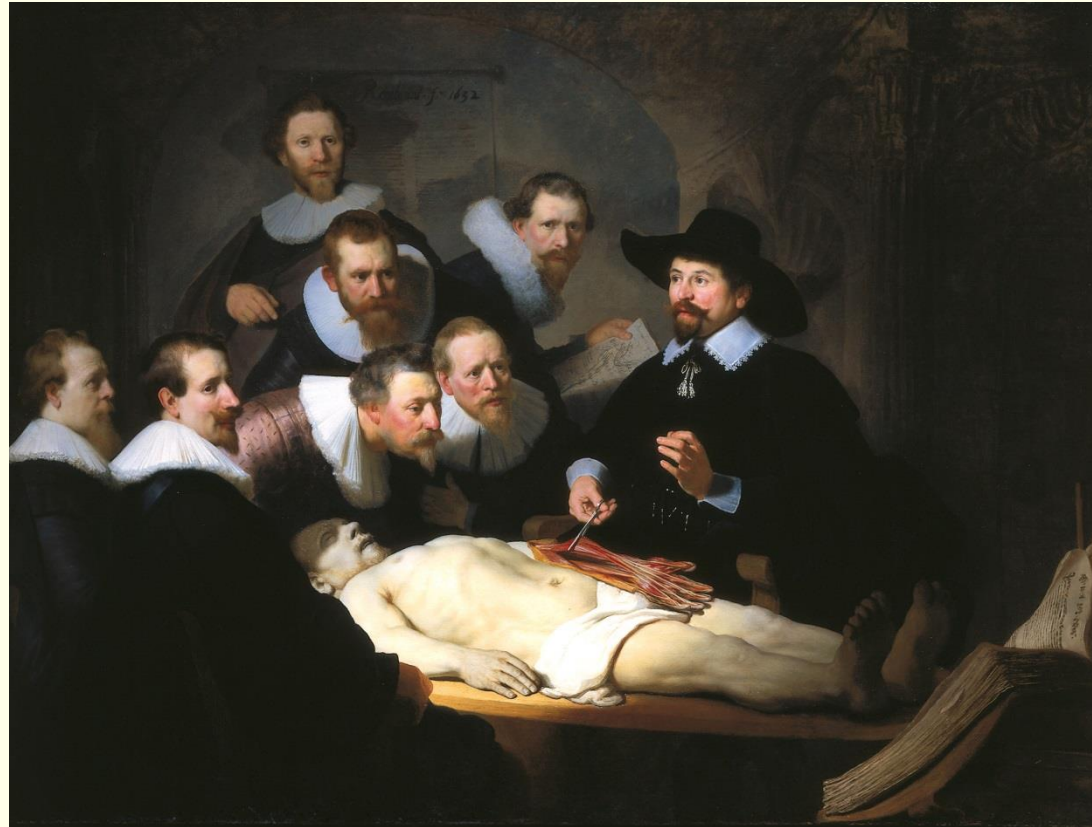

Administration of enema





History of Medical and Veterinary Illustrations



Rembrandt, Anatomy lesson of Dr. Nicholaes Van Tulp (1632)



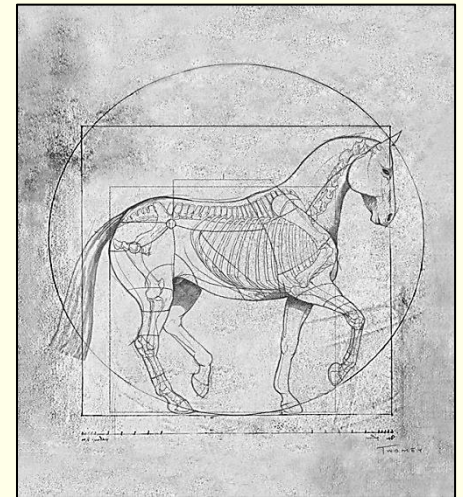

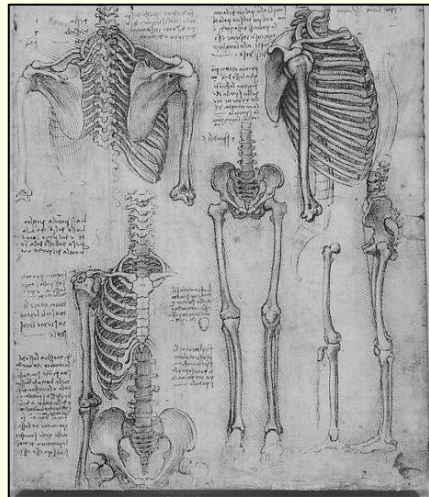

How Old are Medical and Veterinary Illustrations ?

Before the 16th century: Main medical science was *Human Medicine* and *Human Surgery*. Numerous books contain medical illustrations.

Artists rediscover the classical traditions of Greek art: observation of natural forms.

Artists such as **Raphael** and **Michelangelo** performed their own dissections.

Leonardo da Vinci was interested in the study of proportion in man and horses and published important anatomical works.





How Old are Veterinary Illustrations ?

During the 16th century: Physicians and surgeons were consulted for animal diseases. They do treat and castrate farm animals. Poor outcome due to lack of knowledge.

Animal illustrations are found in Medical and Plant text books and studies of artists.

Aim: Illustration of old folk medical practices, e.g. the use of hare limb to treat infections

Erbario I Discorsi, (plant text book) from the Italian physician Andrea Mattioli, 1590



Anonymous, Italy





How Old are Veterinary Illustrations ?

During the 16-17th centuries: Europe is devastated by many conflicts and wars. Life expectancy amongst the nobility is 29.6 years. Exodus of rural populations and their livestock. Shortage of horses for the cavalry. Animal epizootic diseases appeared and their magnitude decimated herds.

Scholars raised the study of animal disease to the status of “worthy of consideration” with the necessity to understand their illnesses and suffering.

Historiae animalium, from Conrad Gessner, considered the first modern zoology book, 1555.

Illustrated by Albrecht Dürer



“Der Feldhase” by Albrecht Dürer, 1502



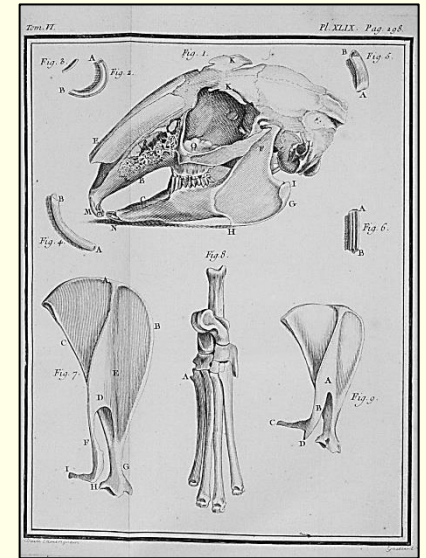




How Old are Veterinary Illustrations ?

Since the 17th century: Zoology evolved in scientific animal medicine over the next centuries and **veterinary medicine** nowadays.

Many detailed etchings about animals and their anatomy were published.

Histoire Naturelle, générale et particulière, avec la description du Cabinet du Roy, from Buffon, 1753.



The traditions of veterinary medicine and illustration emerged together in Europe.

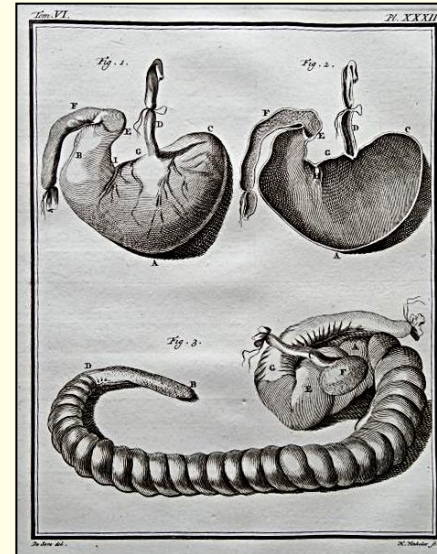




Macro Veterinary Illustrations

Macroscopy: A methodical analysis of the living beings is done and every detail is observed and studied without use of enlarging tools.

Macroscopic observation of a living being is a perilous exercise. When done carelessly, it leads to wrong conclusions and a compromised diagnosis. And to a wrong treatment.

Histoire Naturelle, générale et particulière, avec la description du Cabinet du Roy, from Buffon, 1753





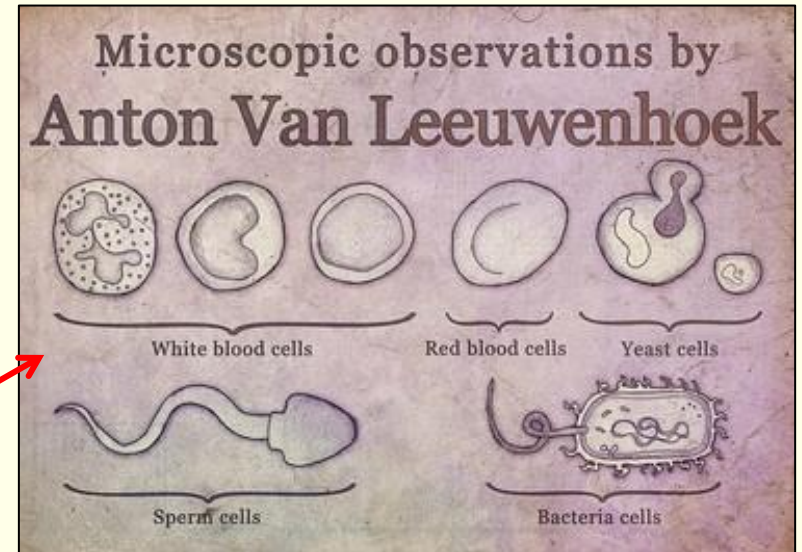
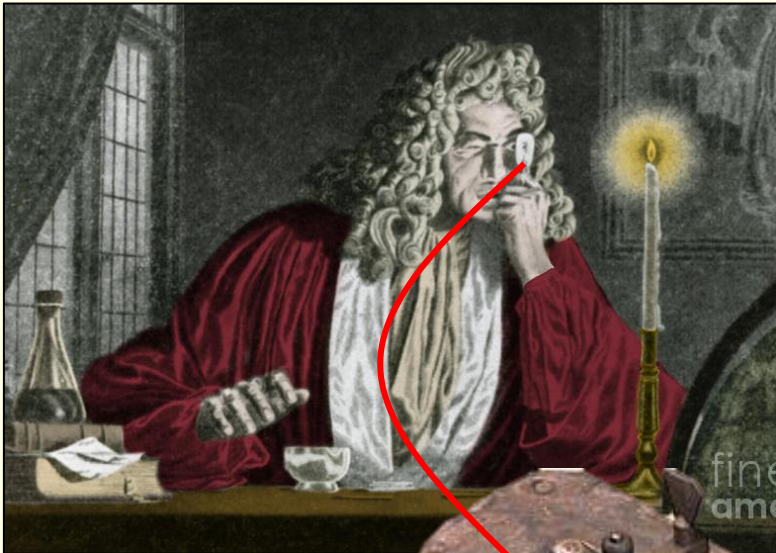Micro Veterinary Illustrations

Microscopy:

A meticulous analysis of collected samples of tissues, body fluids, dust, etc. is done thanks to the use of enlarging tools.

1665:

The microscope was invented by the father of microbiology: Anton van Leeuwenhoek.




He discovered components of the blood, sperm cells, bacteria, and... animals living in dust.



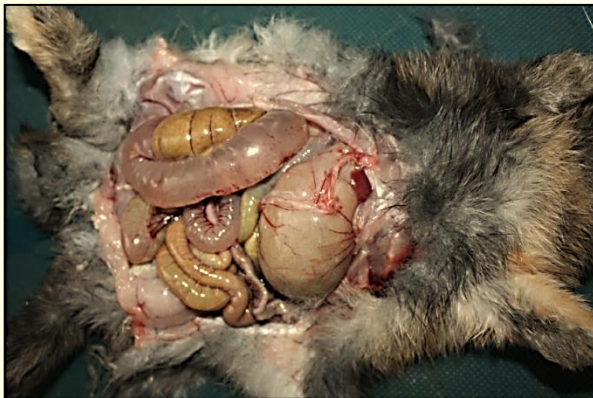
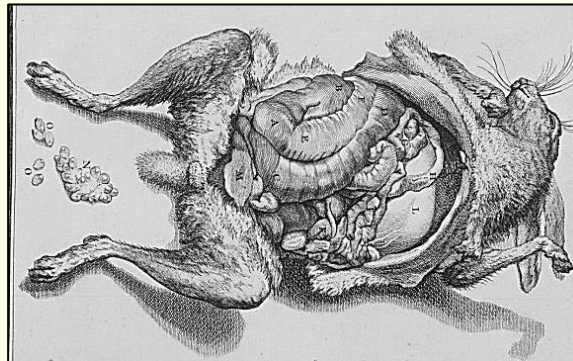
Problem of Veterinary Antique Prints

1. Artists were asked to produce illustrations only from descriptions.
2. Artists were highly influenced by the interpretation of physicians and animal scientists.

This led to amusing illustrations of animals in zoology books of the 18th century:



Same breed



Same ailment: Shope papilloma

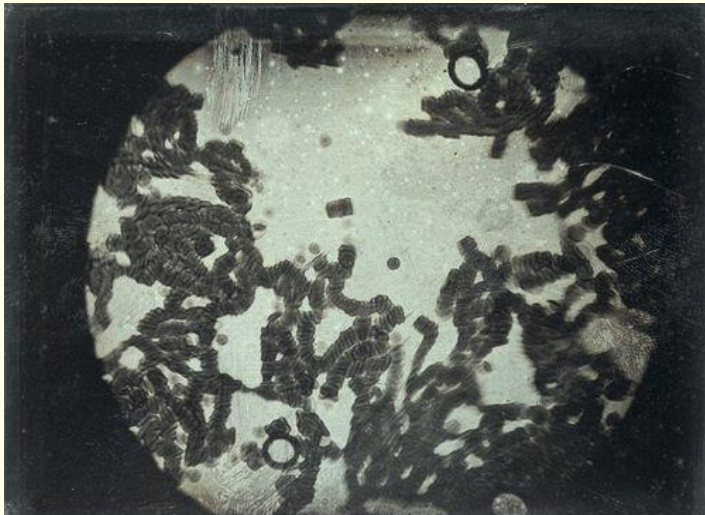




Use of Photography for Medical Illustrations

- 1839:** Louis Daguerre presented his brand-new photographic technique: daguerreotype.
- 1840:** The physician Alfred Donné was quick to realize the merits of photography. He adopted the services of this powerful new ally for his research: capture microscopic images of body fluids to spice up his lectures.

A. Donné is a pioneer in the use of photographs for medical and scientific illustrations



Rouleaux of blood corpuscles.
Daguerreotype, photomicrograph

Medical photography is as old as photography itself !!!



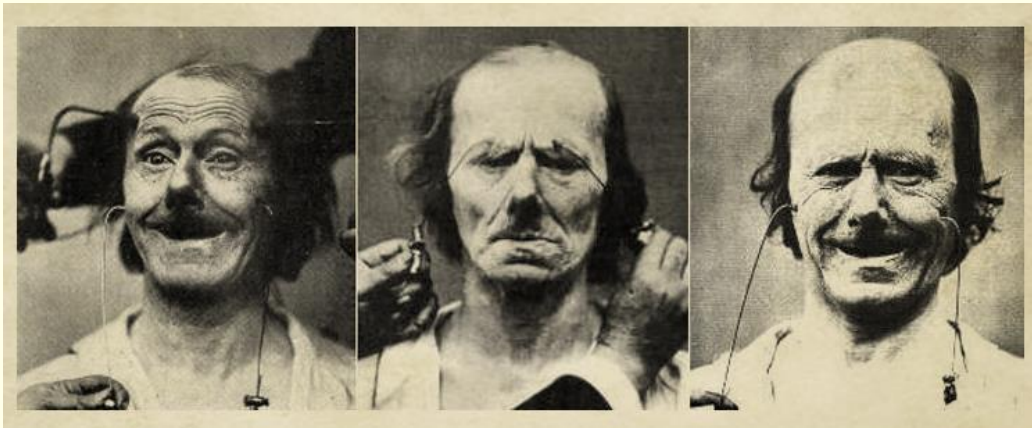
Use of Photography for Human Medical Illustrations

Physicians started to use photography as a tool to illustrate diseases and visual signs of insanity (mental illness).

1847: Earliest known medical photograph by Hill and Adamson: woman with goiter.



1862: *Mécanisme de la physionomie humaine*: photographs of facial expressions and emotions based on the muscular action, the most remarkable of all photographically illustrated books in medical science.



G.-B. Duchenne de Boulogne, The mechanism of human facial expression.



Problem of early Medical Photographs

Attempts to publish early medical photographs in anatomy text books had limited success in the early years of photography.

Several reasons made photographs difficult to interpret:

- Spectral sensitivity of early photo materials to blue, violet and ultra-violet light;
- Lack of textural and tonal variations;
- Depth of field and distortion due to lens design and lens to subject distance.



Photographs had to be retouched or redrawn to make the structures obvious.

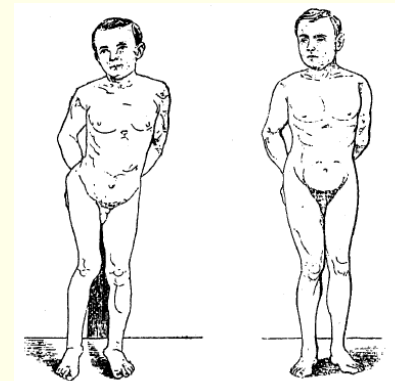
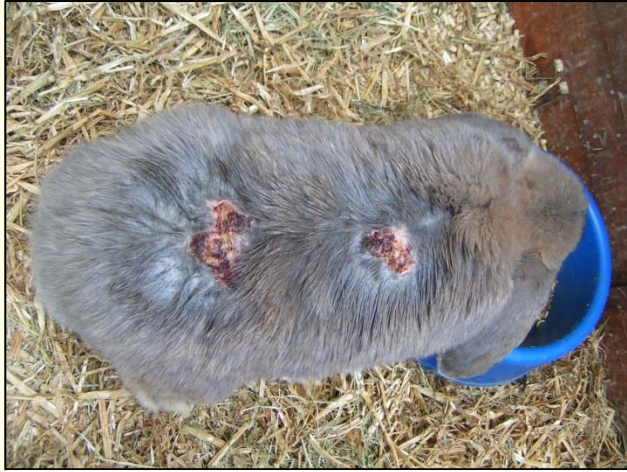

Figure 6. Woodcuts after photographs by H.W. Berend (1859).

As techniques improve and simplify, photography imposed itself among scientists.



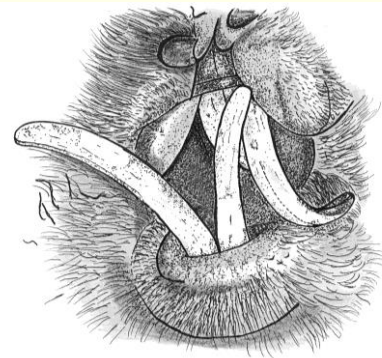
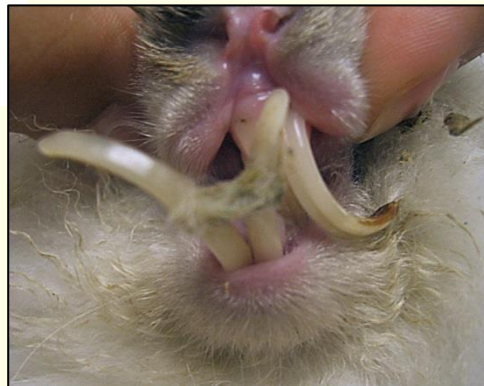
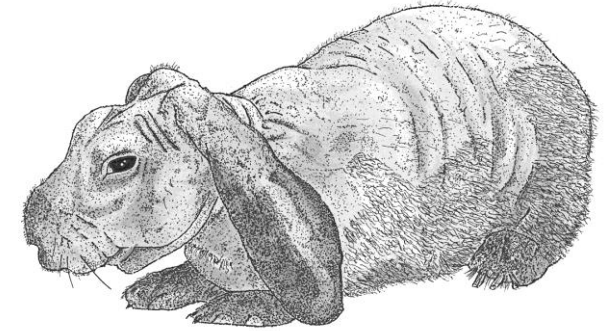Drawings based on photographs is still used today...



The technique of black and white ink drawings based on a picture helps bring to attention skin wounds, a particularity of fur growth or overgrown front teeth, by removing all the “noise”.



It also creates a personal style, e.g., for a book.

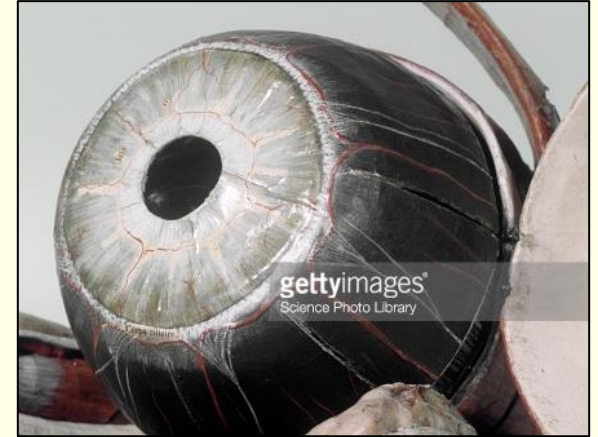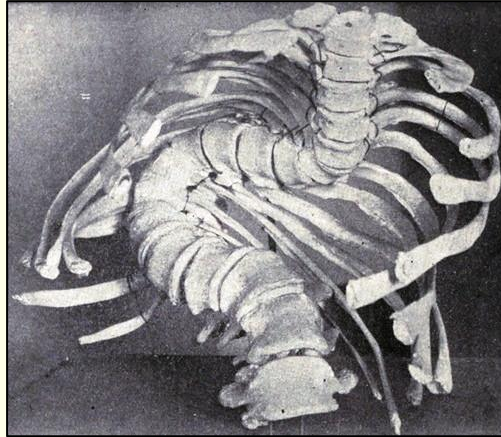

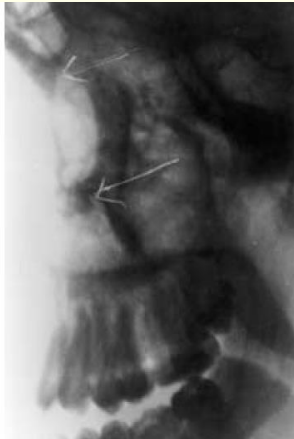
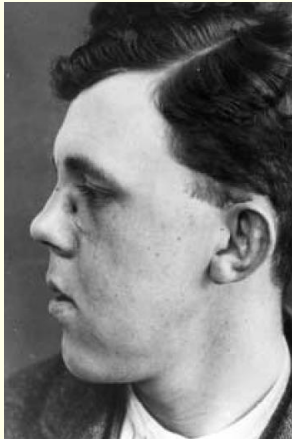

Medical photography plays an important role

1900: Most major centers of medical education now use photography as a method of documentation and study .

Medical photographs is used mainly in radiology, pathology, ophthalmology and motion.



1931: Photographers working in human medicine came together at Yale University (USA). *Biological Photographic Association* and the *Journal of Biological Photography* were created.



Veterinary photography develops after WW2

After WWII: The profession of veterinary photographer was considered “half-skilled”. Instead, veterinarians with veterinary clinical careers moved into specialist photography in response to a growing demand for services.

Equipment was minimal, self-made and darkrooms were often borrowed.


Cameras Pentacore 1950's Ernemann detective 1920's and different lenses for macrophotography



Ernst Leitz Wetzlar flash from 1950's



Camera adapted on microscope, 1954



Individuals developed means of handling their own photographic requirements. As a result, there were no established standards for taking pictures, or to share knowledge through training and apprenticeship.



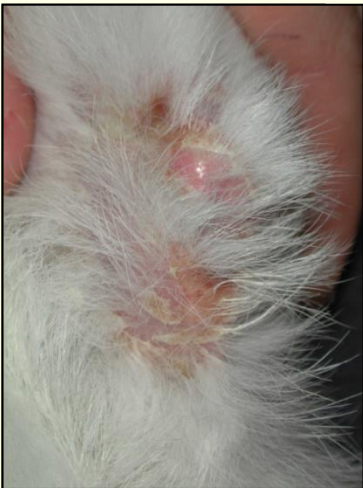Veterinary photography now: generalist or specialist

Many photographers work in a central photographic services within a veterinary faculty or in private biomedical communication companies.

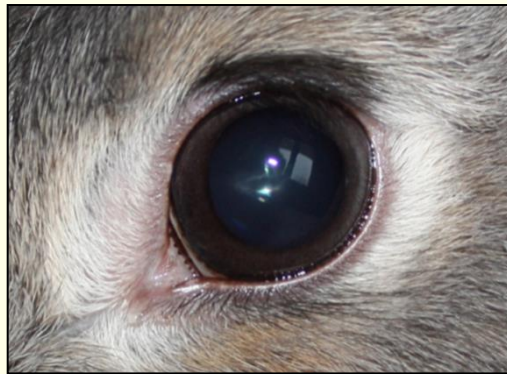Some are generalist and photograph all topics.

Most specialize in a field of medicine:

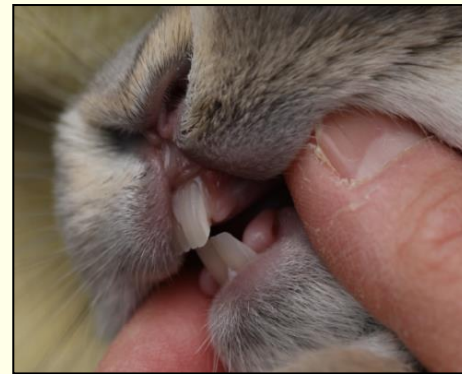Dermatology
species



Ophthalmology



Dentistry



or an animal





Veterinary photography nowadays: requirements





Have manners, be sensitive and make comfortable

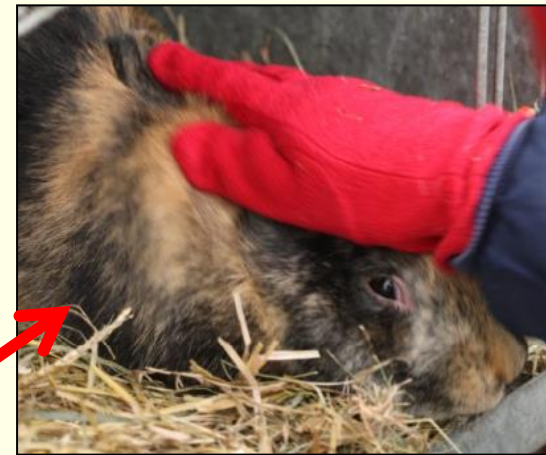The photographer is asking a favor to the animal, that it cooperates and allows handling in a position that may be uncomfortable.

It needs sensitivity to the animal's condition and dignity during the photographic procedure.

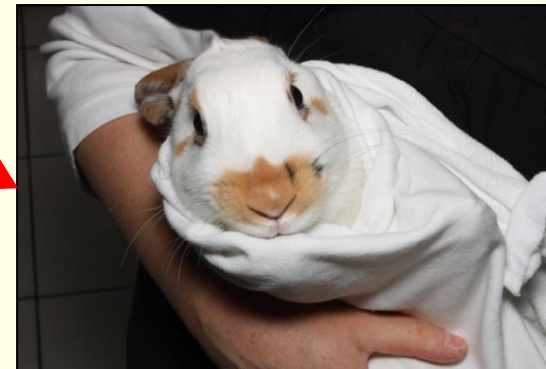Gaining trust is very important...



Tact and patience are needed to calm down a frightened or aggressive animal. Sometime it means wearing gloves.



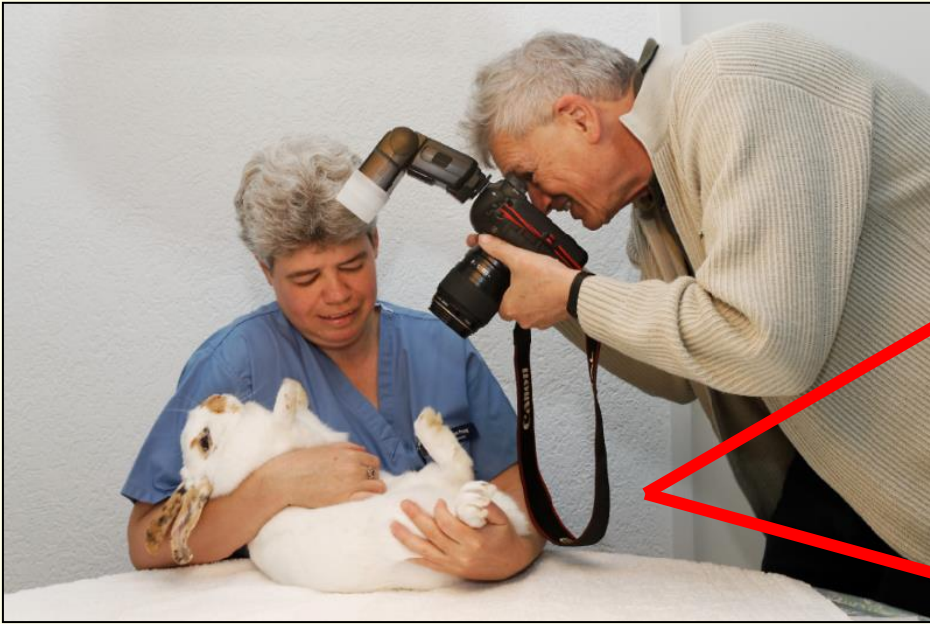Respect the dignity of the animal, especially when it is restrained or sick.





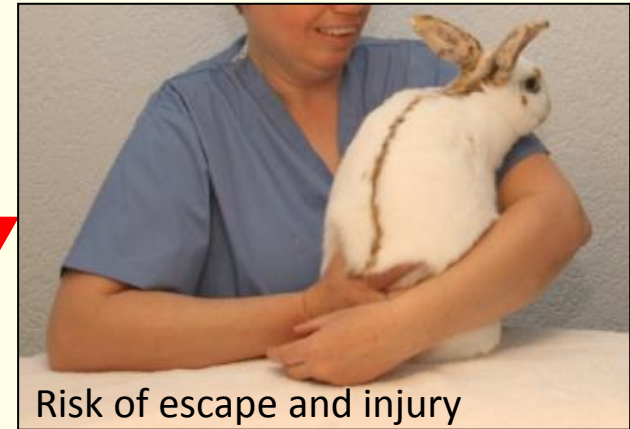Be responsible !!!

Handling and positioning an animal that did nothing wrong.



It must be done in a calm place, with soft light and no noises of other animals, e.g. barking of dogs.

A noise of the camera, an unusual movement may startle the animal.



Risk of escape and injury



Risk of defecation to show displeasure

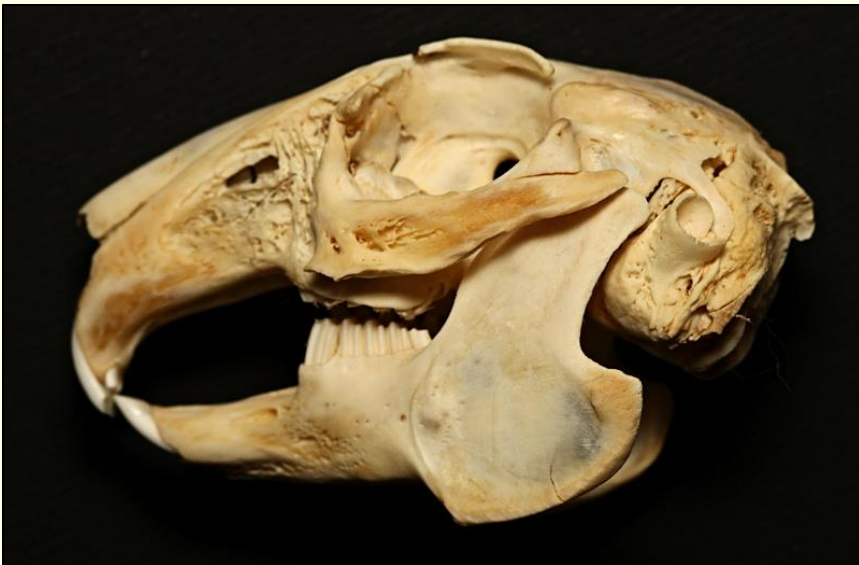

Knowledge of anatomy and morphology

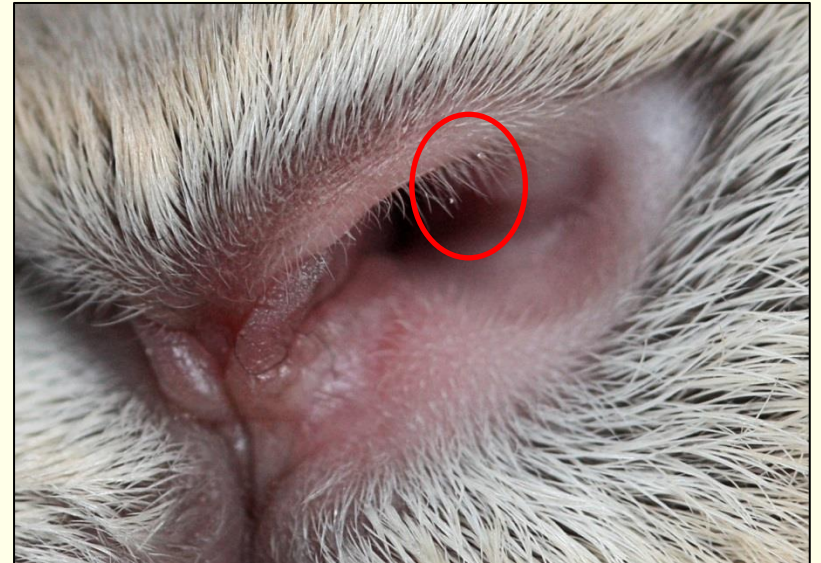A good knowledge of anatomy and morphology of the animal body and a basic knowledge of physiology helps in the examination of animals, recognize modifications.

An understanding of the anatomy helps obtain photographs at the right angle or in a natural position.

This avoids optical distortions and misleading information that may cause misinterpretation.



Note tiny droplets of condensation on nasal hairs





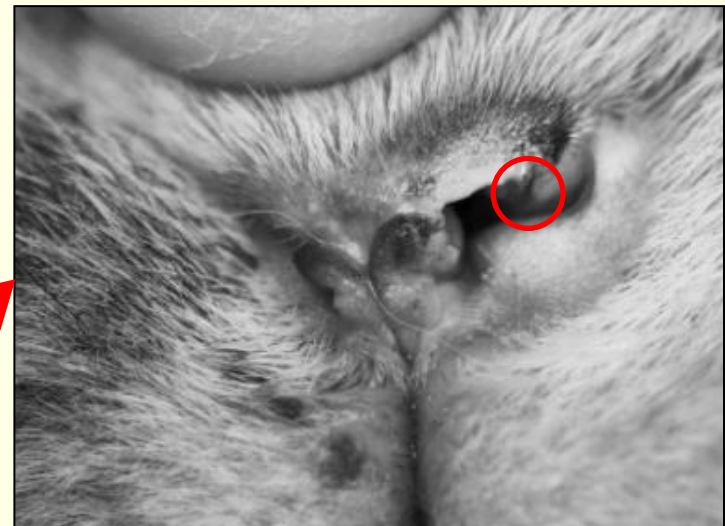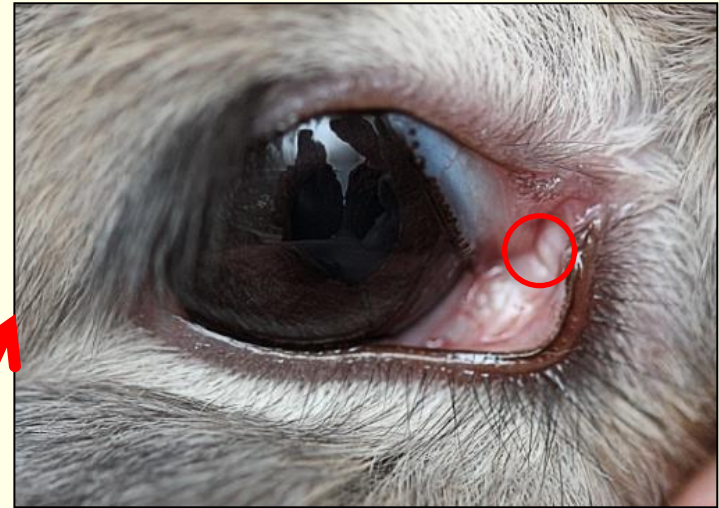Knowledge of medical terms

The knowledge of medical prefixes and everyday terms used in pathology, bacteriology, radiology and surgical procedures is necessary.

Demand from a veterinary surgeon: “Pictures of the inferior lacrimal *puncta* and opening of the nasolacrimal duct in the inferior nasal *meatus*”.

Translation: Pictures of the tear duct opening on the inferior eyelid and opening of the tears duct in the nasal cavity.



Where: in the corner of the eye, inside of the inferior eyelid,
on the side wall, in the nasal cavity.





Be aware of laws and copyright

As publishers own the copyright of the picture, it is important to take several photographs of the same topic, e.g. under a slightly different angle. For other publishers or own usage.





Observe at all times for parasites !!!

Parasitic blow flies on excrement



Tick walking on the foot of a rabbit

Work in live situations can be very stressful.

The photographer must remain calm while taking his camera, the correct lens and flash in order to make good quality pictures in 1/10 of a second...



Veterinary medicine has become visually oriented



WARNING: Although care in the choice of pictures has been taken, this next section may contain pictures that can hurt the sensitivity of some persons.

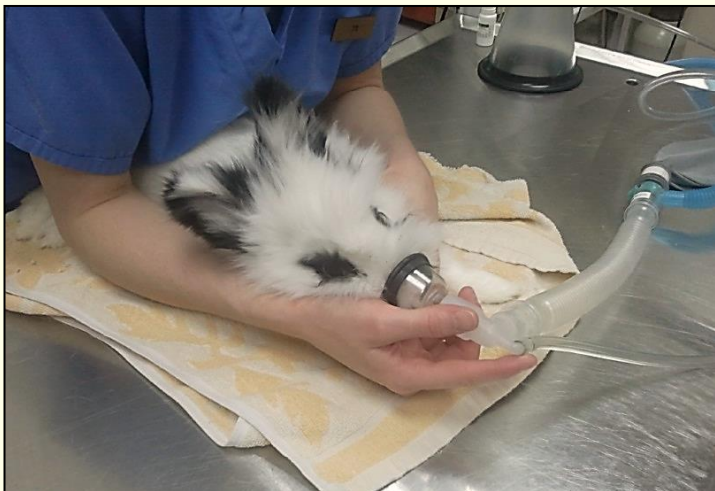

Working environment

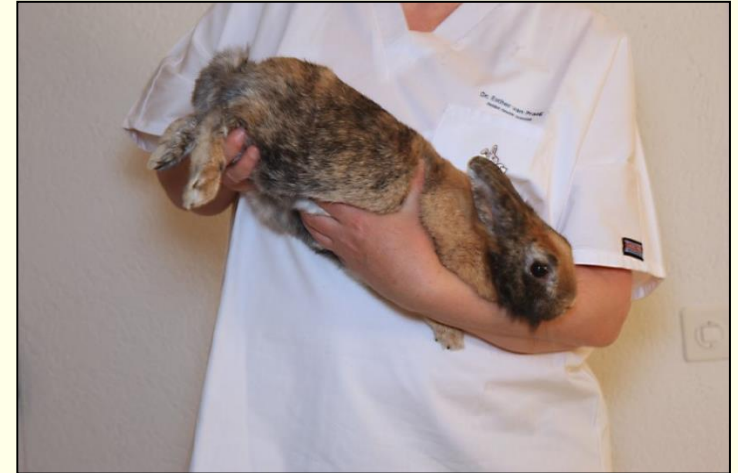

Photographs of the working environment are made to display the conditions and appearance of the wards and surgery rooms, of the instruments used for diagnostic tests, for anesthesia, etc.

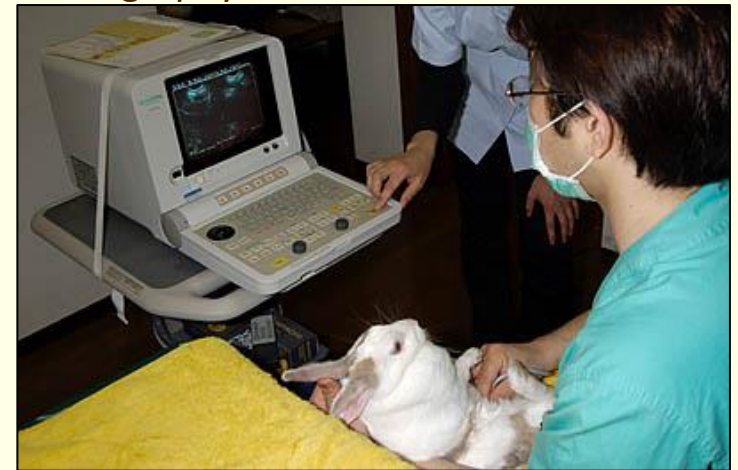Anesthesia machine and rabbit being anesthetized



Reanimation



Echography





Animal in full, healthy or sick

A few days old



Healthy animals must look at their best, groomed, exercised and alert, as well as express the characteristics of their kind.

The photographer can express his style.

The help of the veterinarian or an assistant is welcome to play with the animal and calm it down.



Angora



Lop

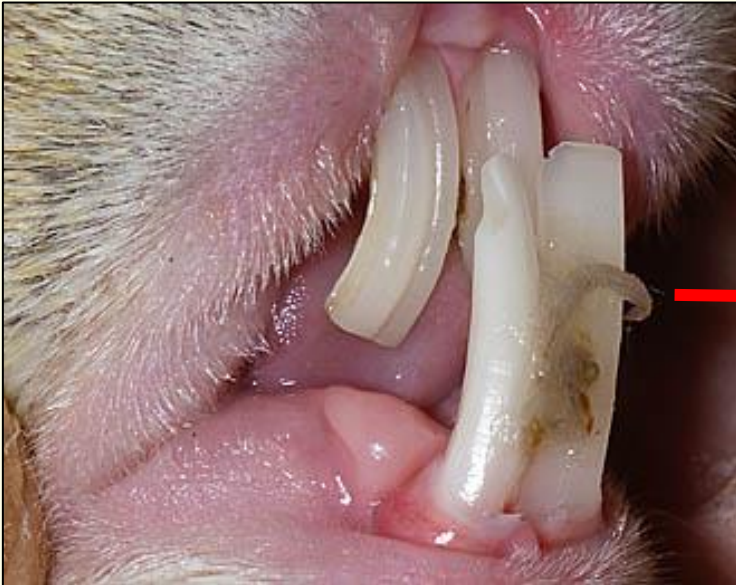



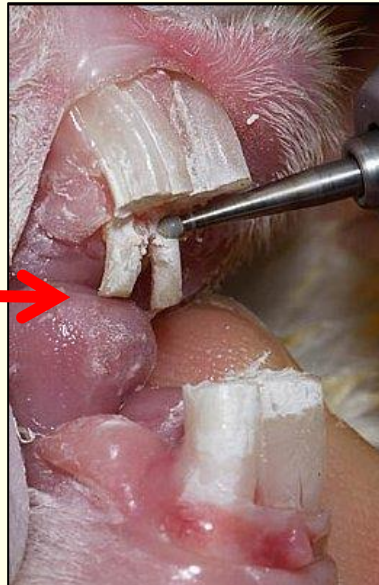Animals in detail, healthy or disorders

Photo-documentation requires an acceptable level of photographic standardization in order to obtain significant and comparable images.

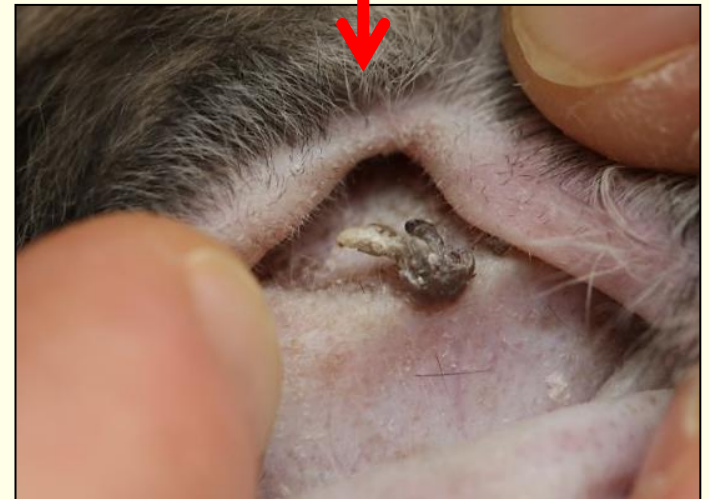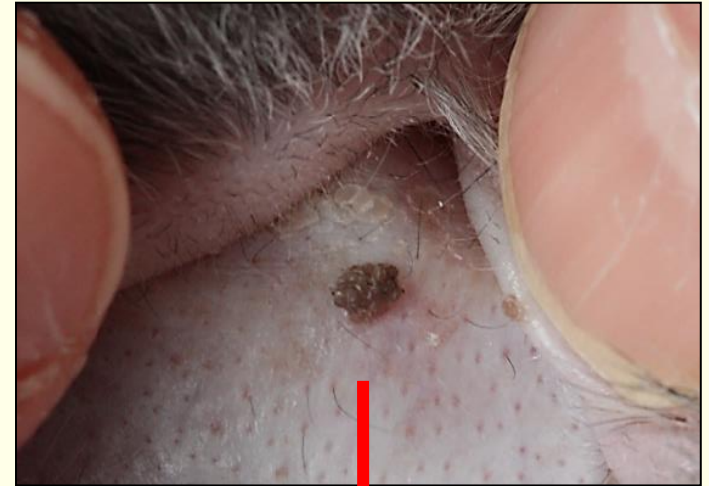Before dental treatment



After



Wart (papilloma) in ear



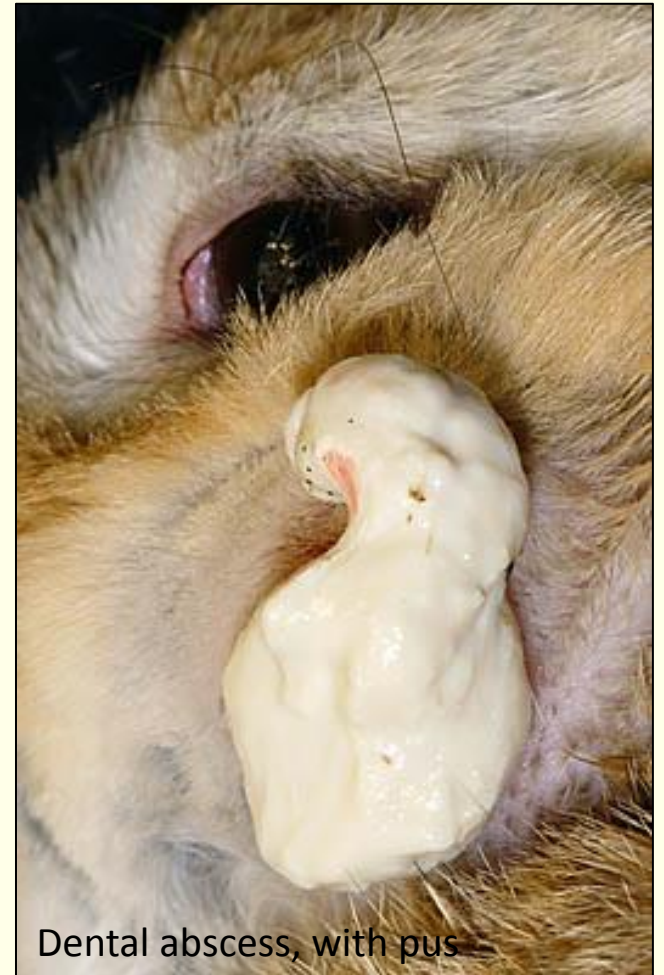
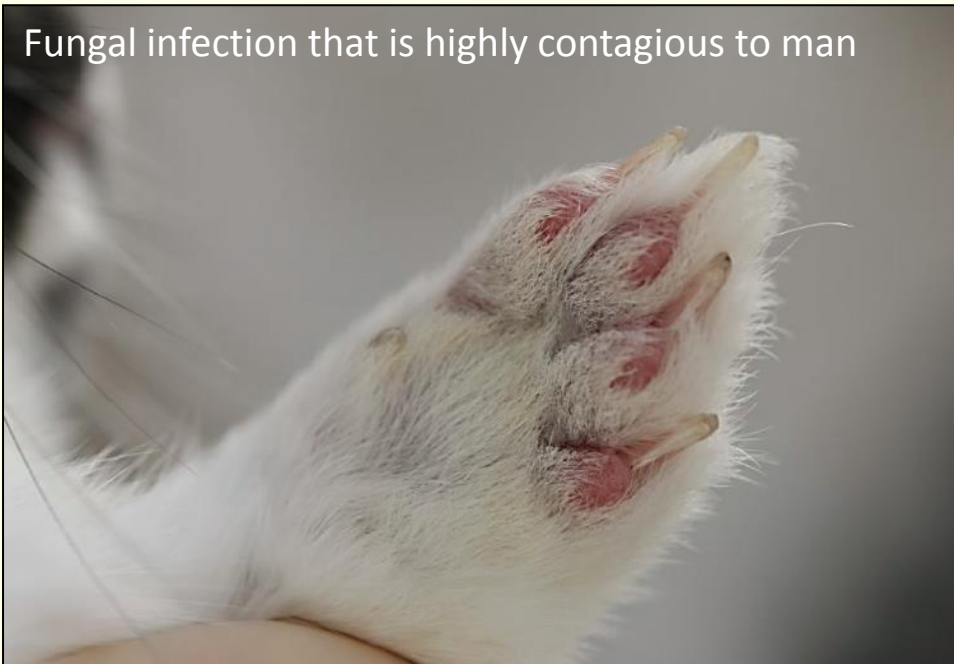
Infectious diseases

The veterinary photographer must remain serene and calm during any emergency or surgery.

He must also be aware that some disease have an infectious nature. He must take measures to avoid contact and protect colleagues from hazardous circumstances.

Fungal infection that is highly contagious to man



Dental abscess, with pus

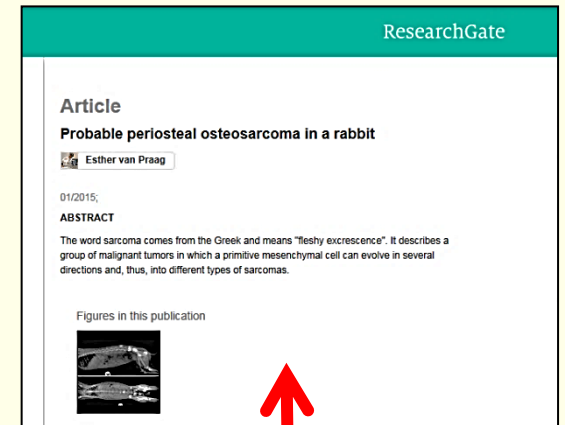


Document the evolution of a disease



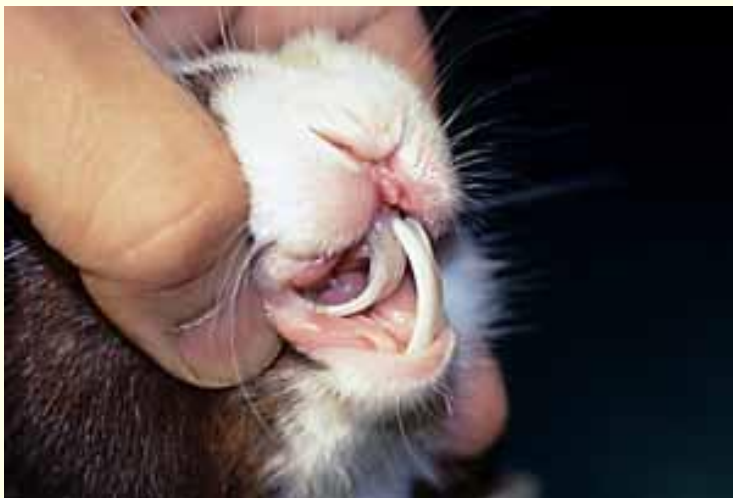Photographing the evolution of a proliferative disease at regular intervals of time can help understand its abnormalities and help in its treatment.

When accompanied by diagnostic test results and X-rays, the photos can be used for a medical case report.

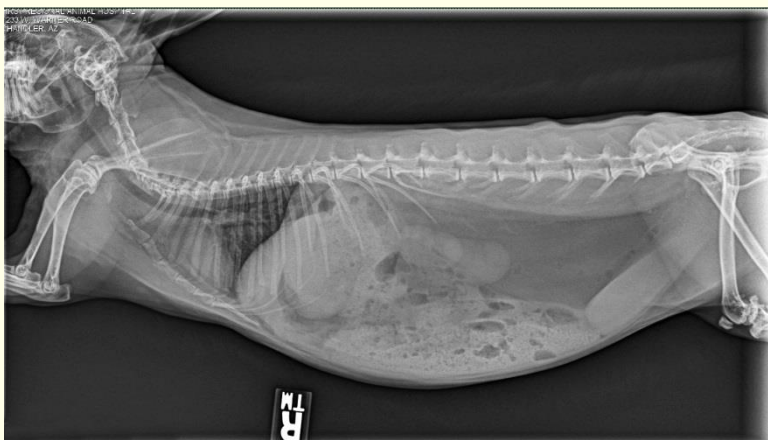
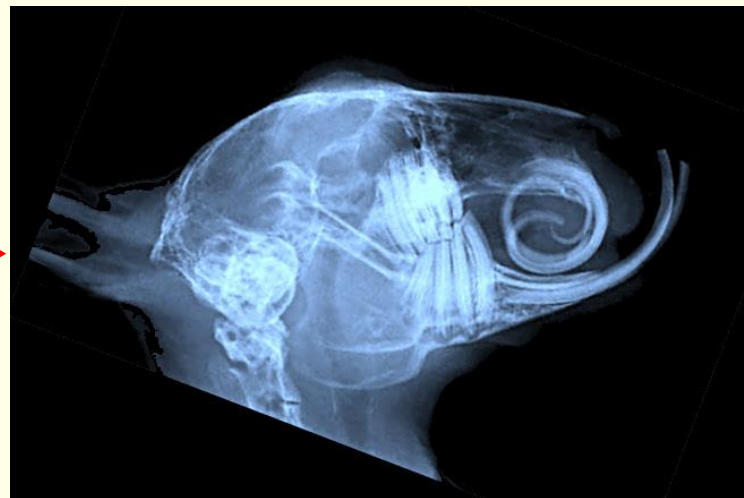


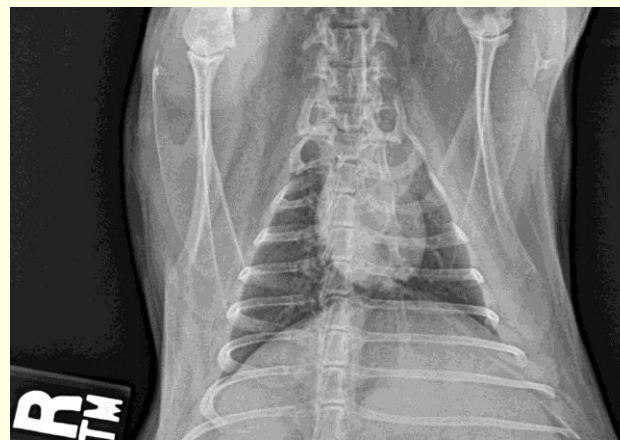Imaging to see the causes of medical problems



Film x-ray

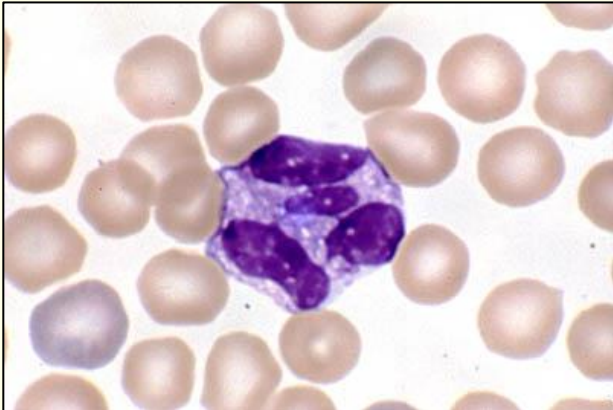


Digital x-ray



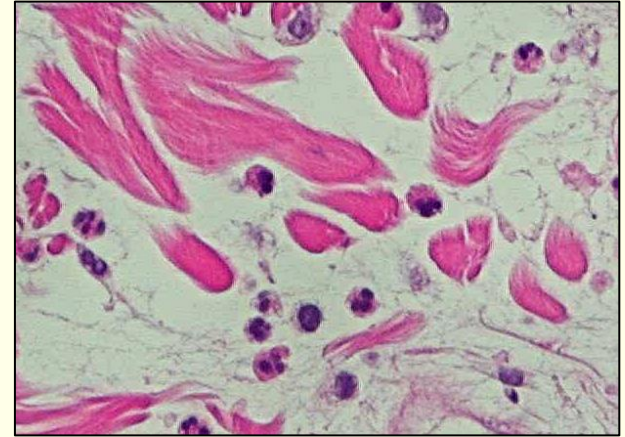


The fine art of microscopy



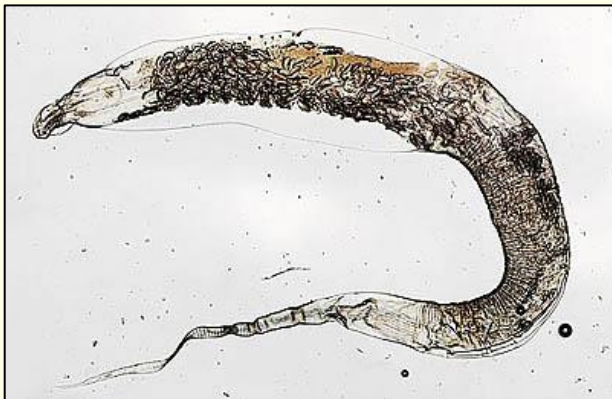Basophil cell

Damaged samples or those with artifacts will have a different visual presentation than excellent samples. It is important not to let the damage become the focus of the photography.

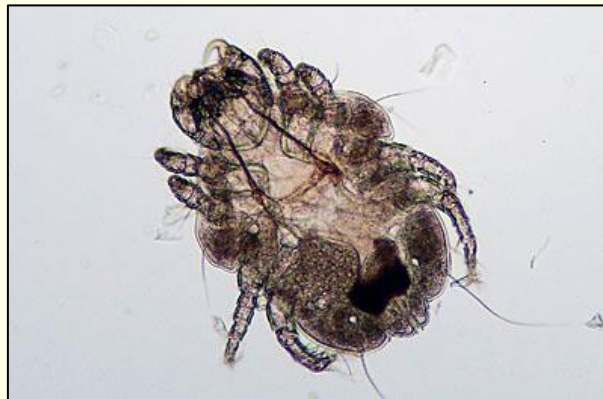

Skin with collagen and blood cells

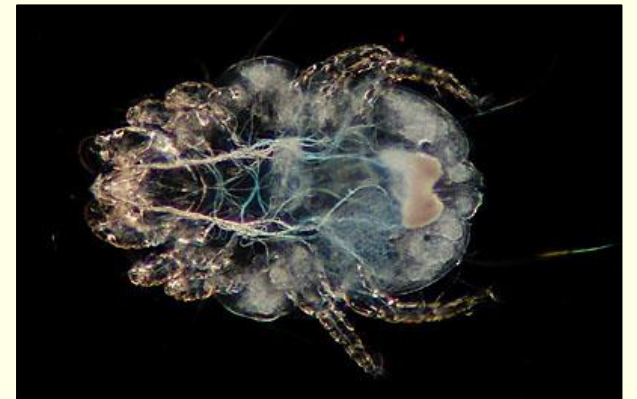Parasitic intestinal worm



Skin mite

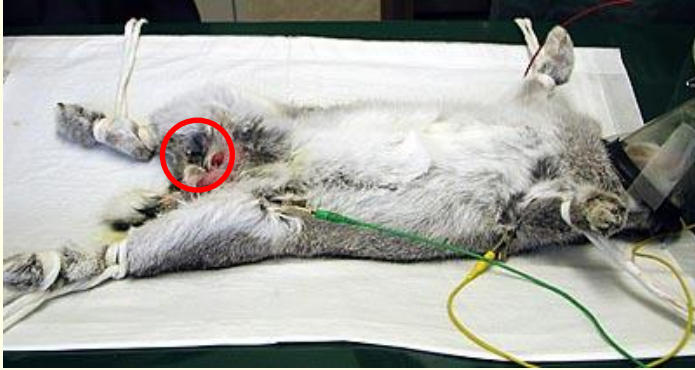


Skin mite in dark phase





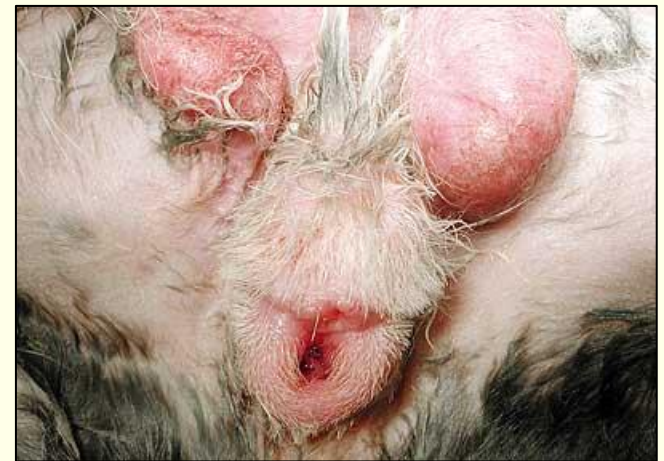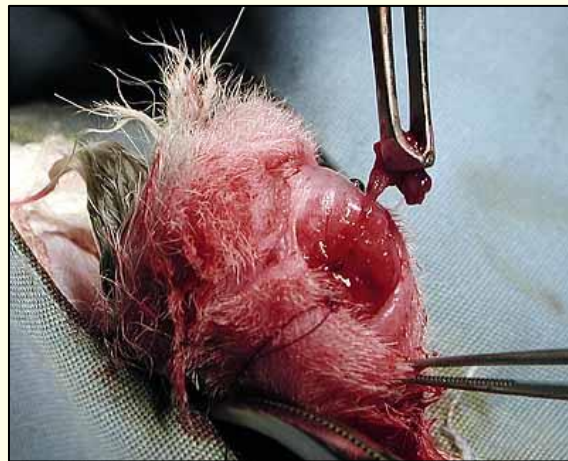
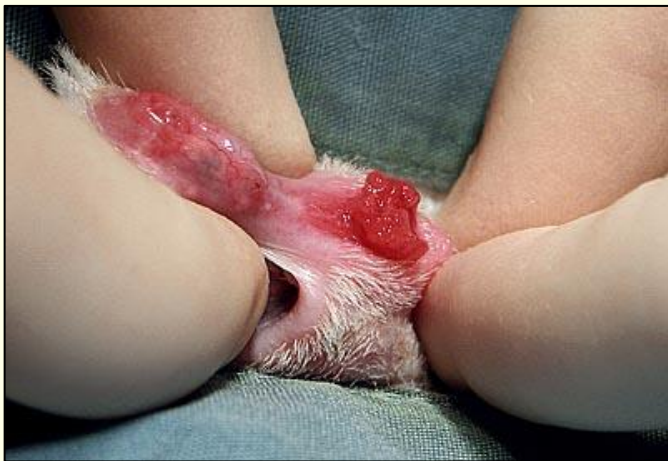Surgical procedure with anesthesia



Photography in the operating room is among the most challenging tasks.

A surgery room is noisy. Yet, it requires careful attention to the emotional and physical environment in the room and respect of the sterile protocol.

Papilloma (wart) on the anus





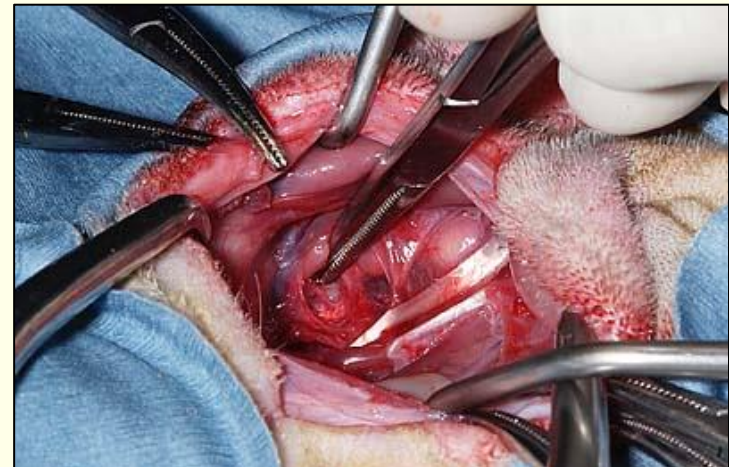
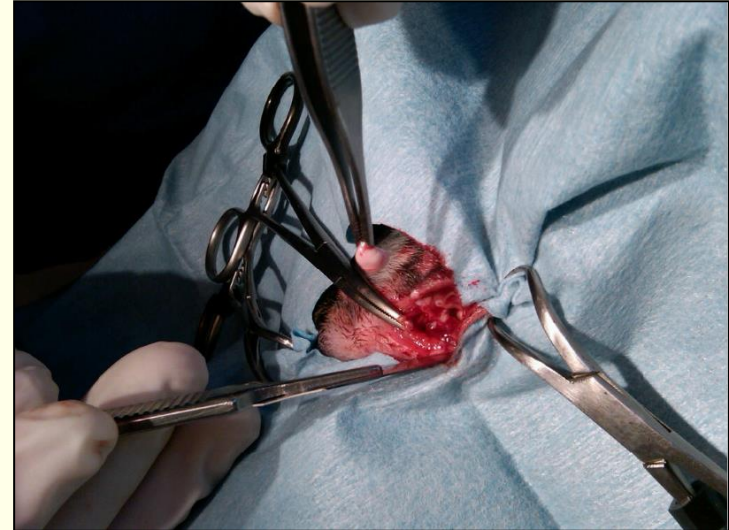Photographing during surgery

A sterile protocol is respected in the veterinary surgery room to minimize the risk of contamination of the patient to microorganisms during surgery.

Use of drapes, sterile instruments, swabs...

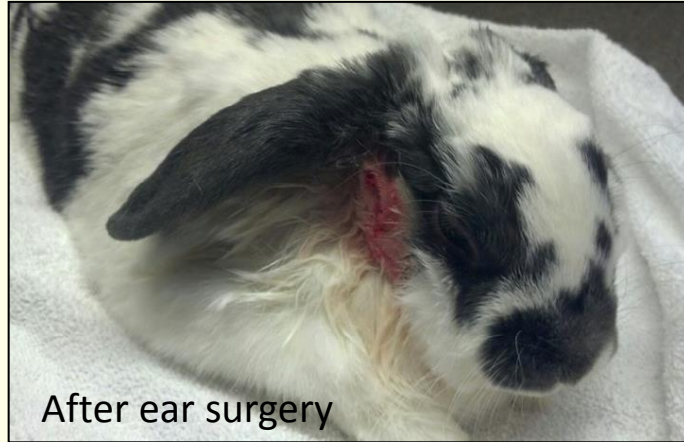This makes photography difficult as it distracts from the area of interest.

When possible, dirty surgical drapes and swabs should be removed from the photographic scene. Or replaced.





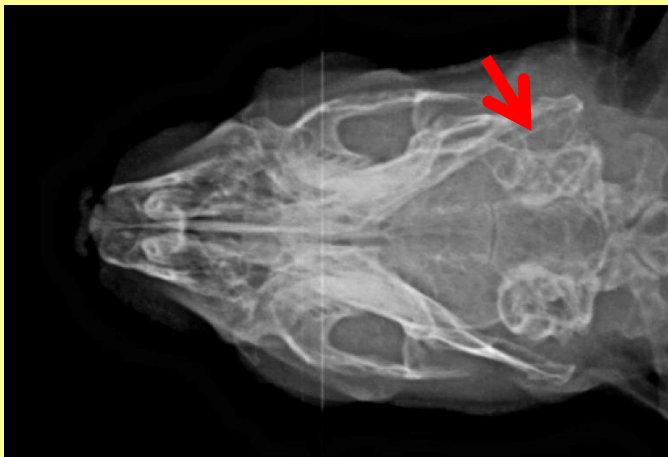Following a patient till recovery



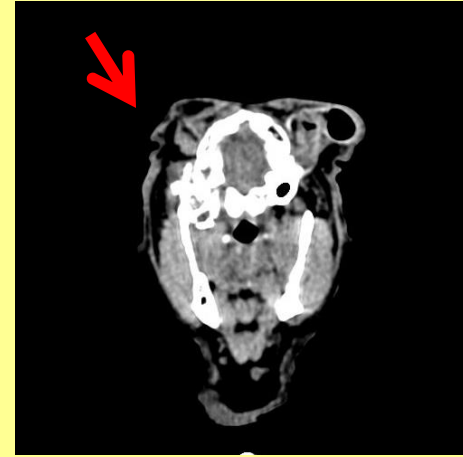Graysie with partial facial paralysis due to middle ear infection from clinical examination to recovery.

Diagnosis

X-ray shows middle ear destruction

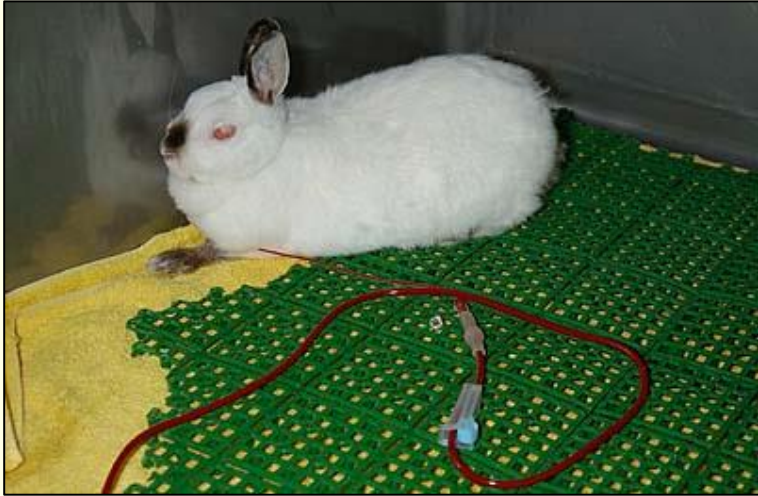

CT scan shows the destruction of the bulla



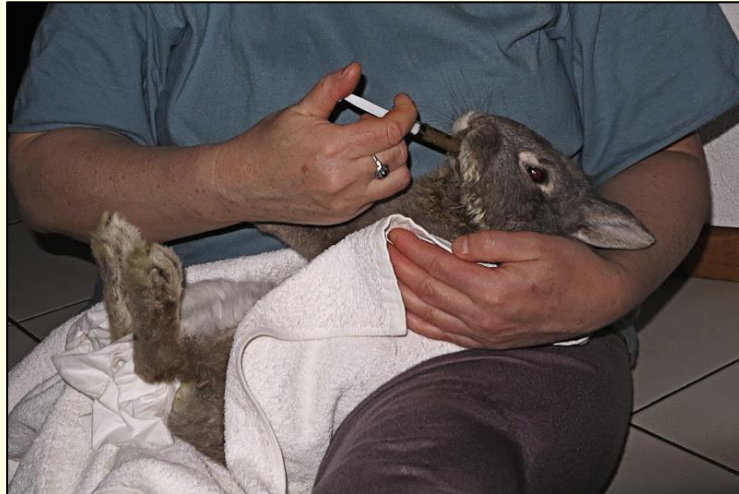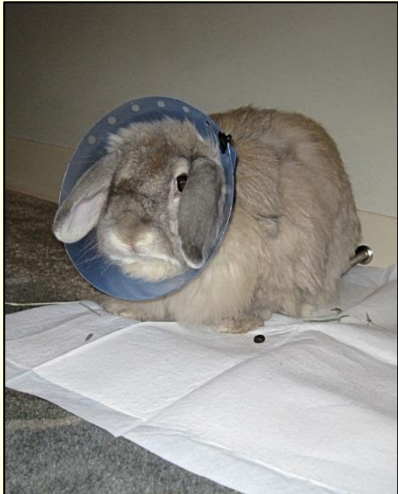


Documenting care after surgery or a disease



Documenting a treatment or care is essential to convey clinical information about the outcome of a disease or surgery.

It furthermore supports critical thinking and judgment of a animal health professional, facilitating consistency and effective communication with the owner of the animals and among veterinarians.

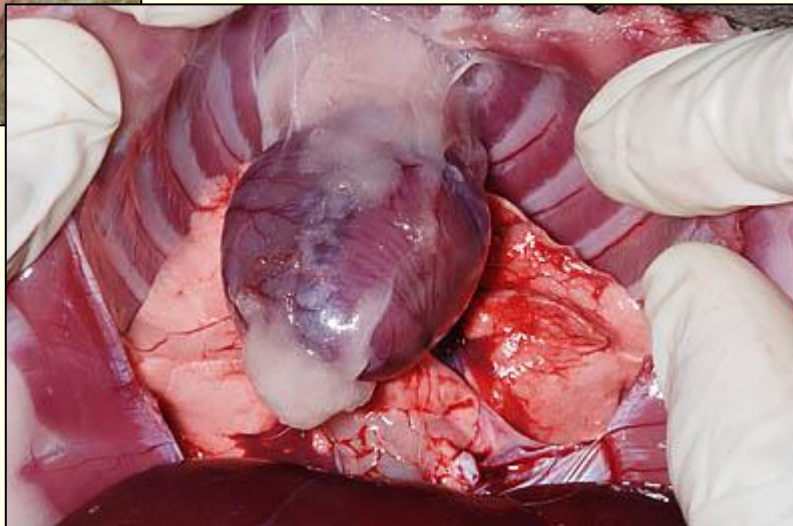
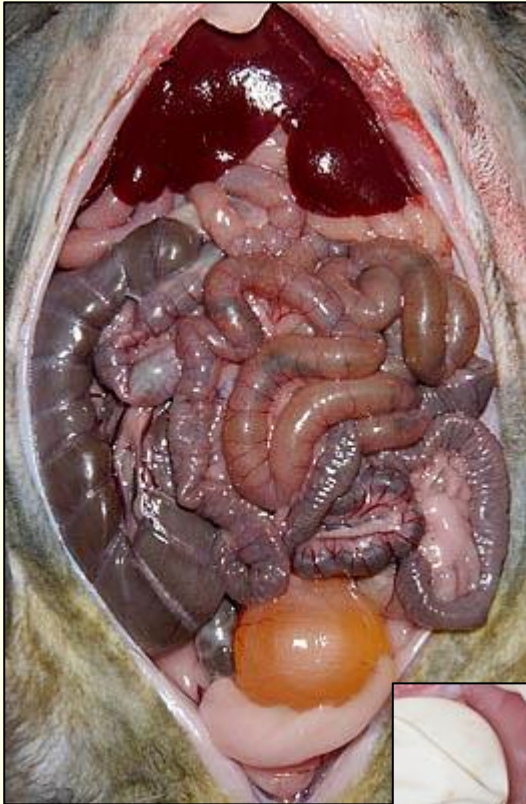




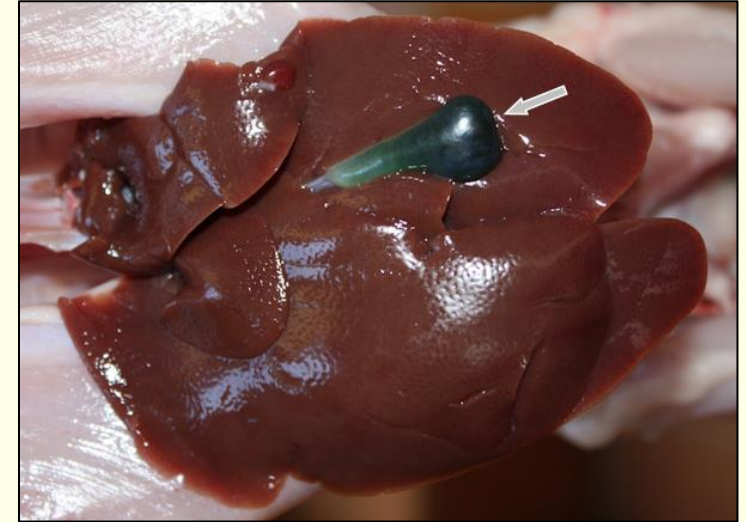
Understanding the cause of death

Working in the *post-mortem* room and photographing the steps of a necropsy and dissection can be very stressful.

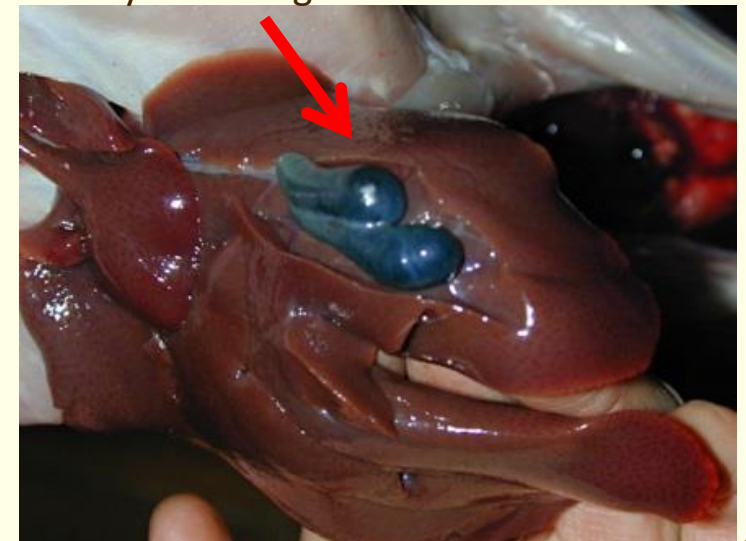
And may bring surprises...



Fat around the heart

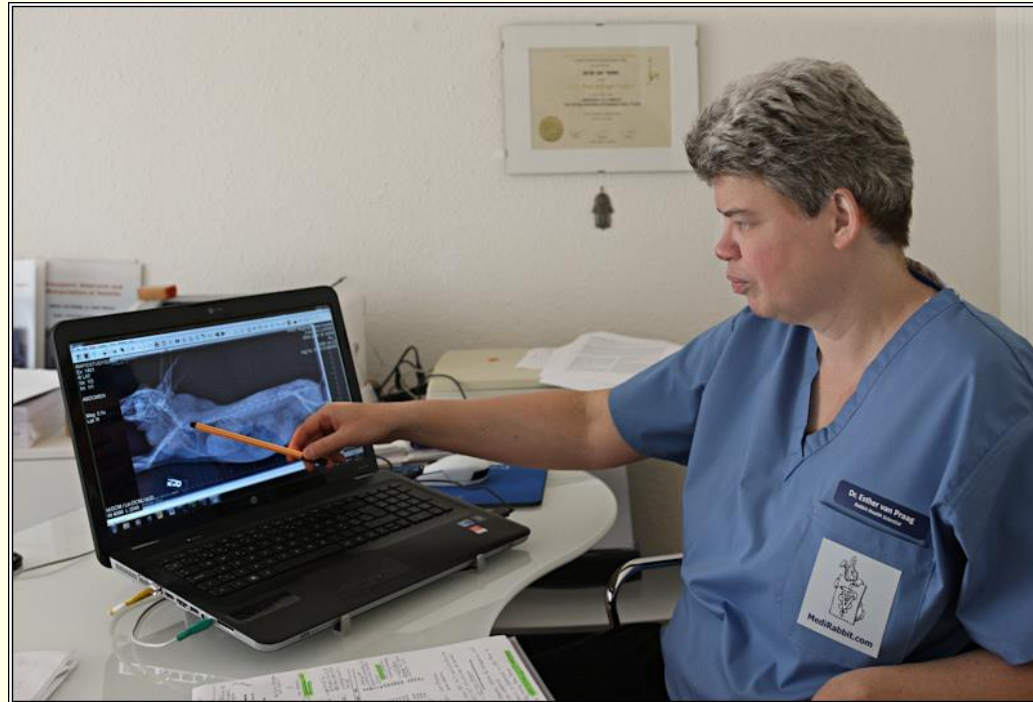

Rarity: double gallbladder





Required material and knowledge





Good knowledge of photographic material

The standard set-up includes:

- The popular 35 mm single reflex lens film and/or digital camera with a range of lenses;
- Long focal macro lens;
- Lighting equipment;
- Video camera.

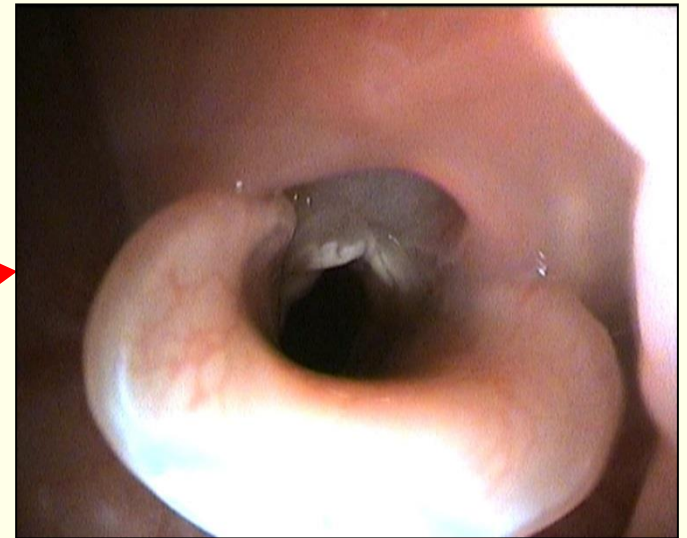
Unusual equipment is sometimes required:

- Large format cameras;
- Set-ups for micro or macrophotography;
- Flatbed scanners for film radiographs;
- Endoscopic and ophthalmic cameras.

Data storage:

- Computers for editing, storing and filing images;
- Network for rapid transmission of results.

Endoscopy of space between vocal cords (glottis in a rabbit



Dr Oméro Sessini

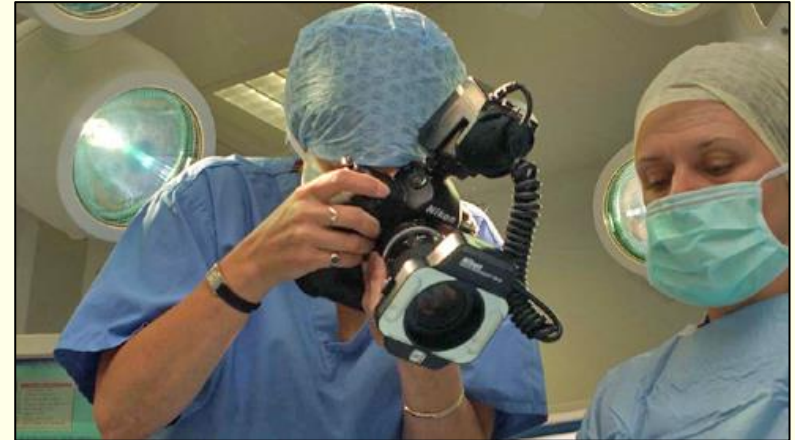

Good understanding of technical requirements

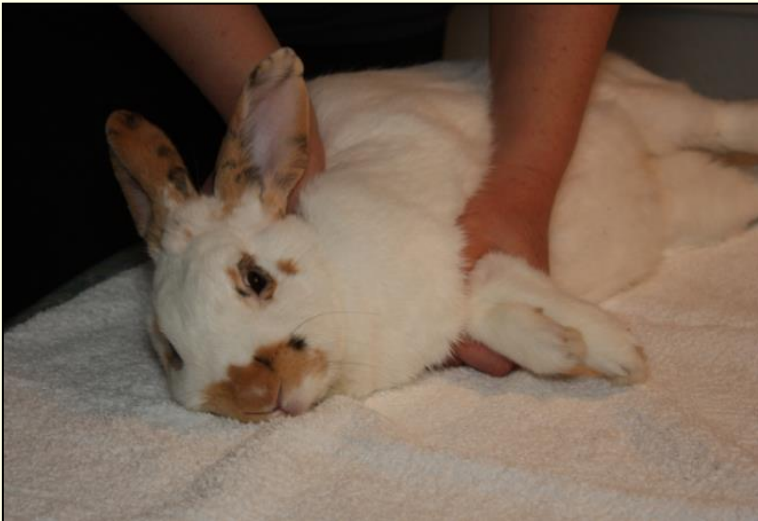In a surgery ward.

The photographer will confer with the surgeon and his team in the placement of his camera and lights, their positions and angle in regard of the operative field.

A plain white sheet can serve as background.



<http://www.turicia.com/blog.cfm?pagina=11>



Showing the position for oblique skull X-ray

In the studio.

A change in color cast must be avoided, e.g. appearance of the skin or fur color. A neutral background is necessary: white, gray or blue.

When a black background is used, the animal should be correctly lighted to keep the profile and details of the fur.

It is, furthermore, important, that the animal feels relaxed in the studio environment.

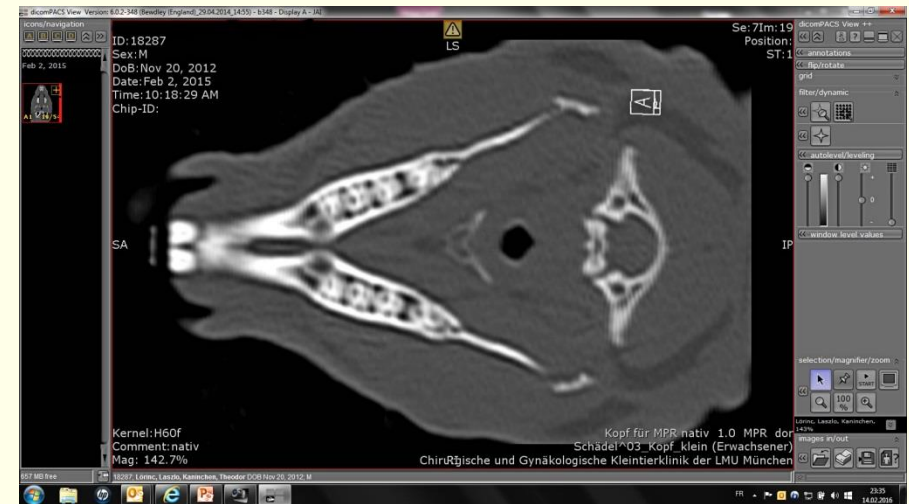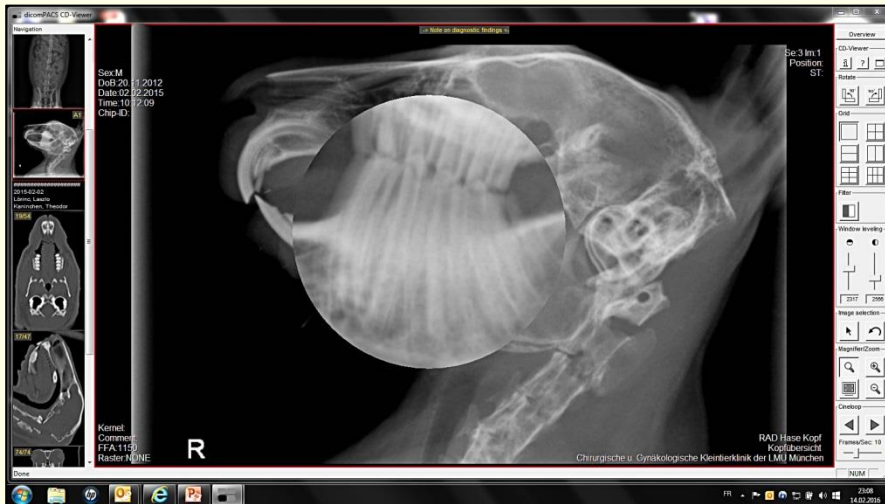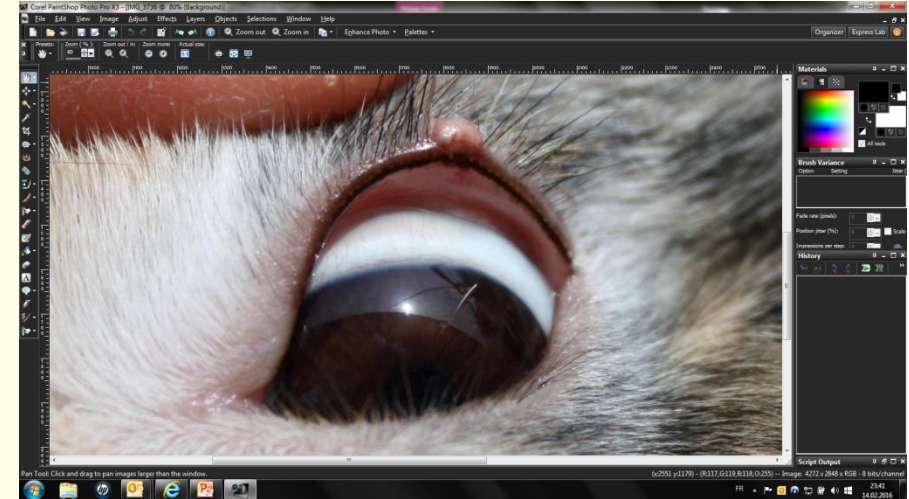


Photo editing and digital imaging

Photo editing software is important for a high quality output of images and desktop publishing:

- Software for photo editing;
- Software for state of the art medical images in DICOM format, such as x-rays, CT scan.

When editing photographs, it is important to maintain scale and color balance.



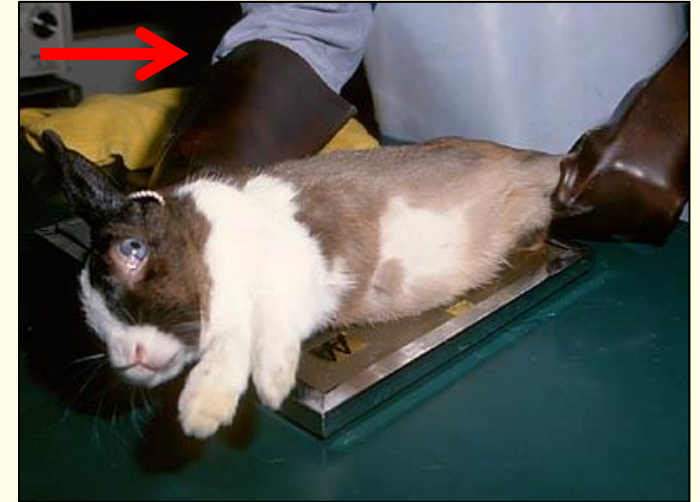Software for viewing, editing, and de-identifying DICOM digital X-ray and CT scan images



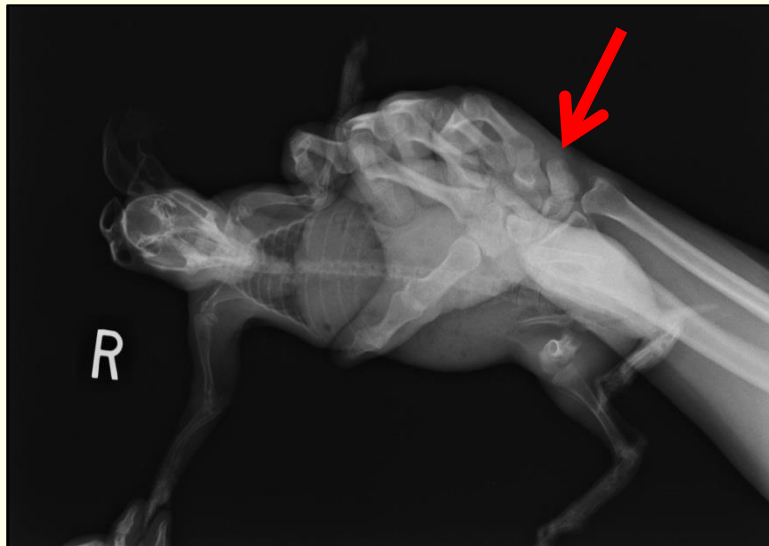X-ray curiosities obtained for analysis...

Fundamental to radiation protection is the reduction of expected dose and the measurement of human dose uptake.

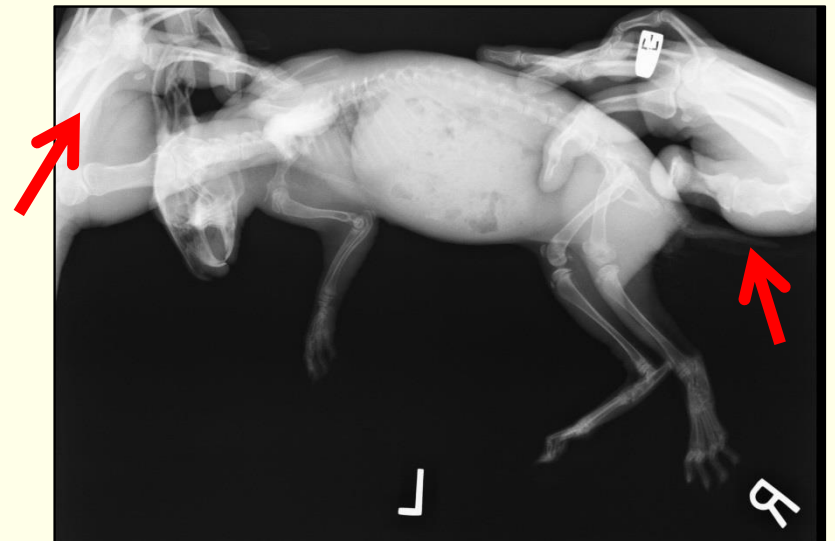Special clothes and gloves protect against radiation even if heavy and unpleasant.



R = right side, while this is a ventro-dorsal view

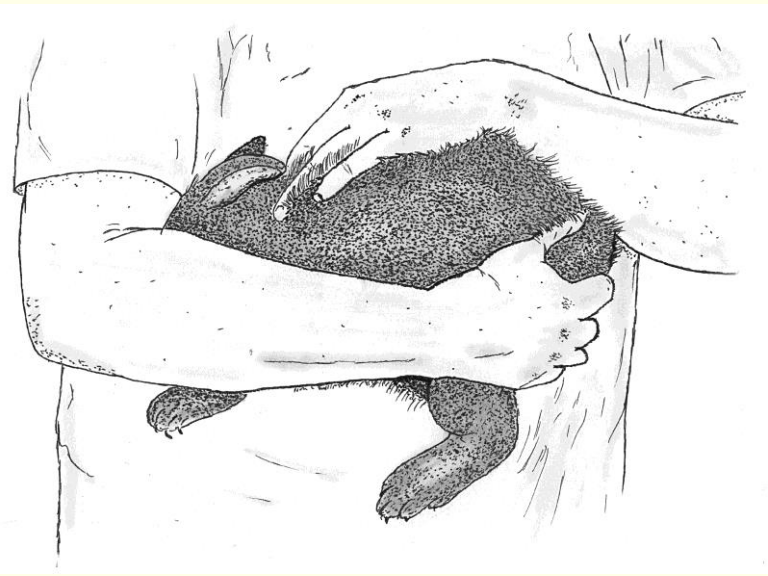
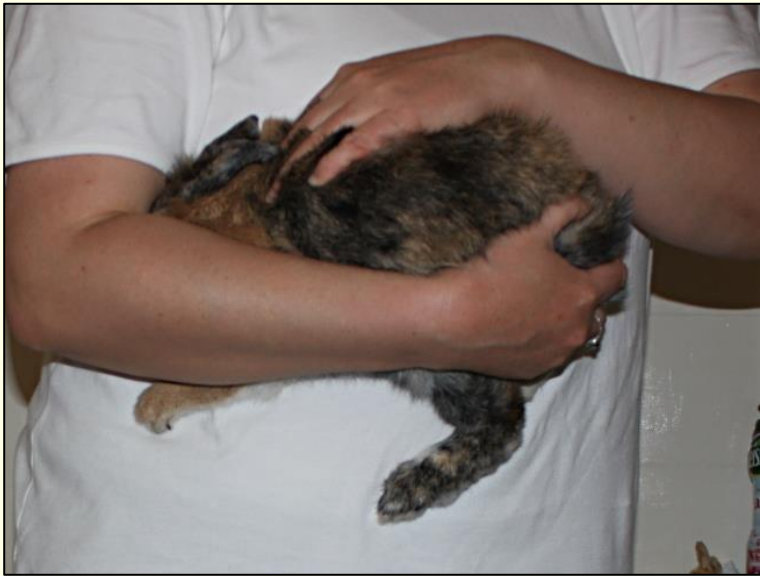
R = right side, L = left side, which one is ok ?





Role of Veterinary Illustrations

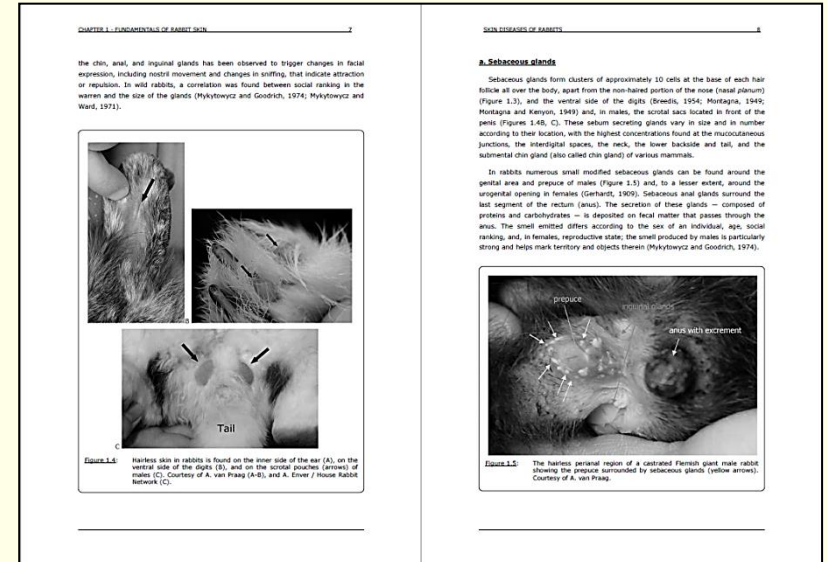




Veterinary publications and books

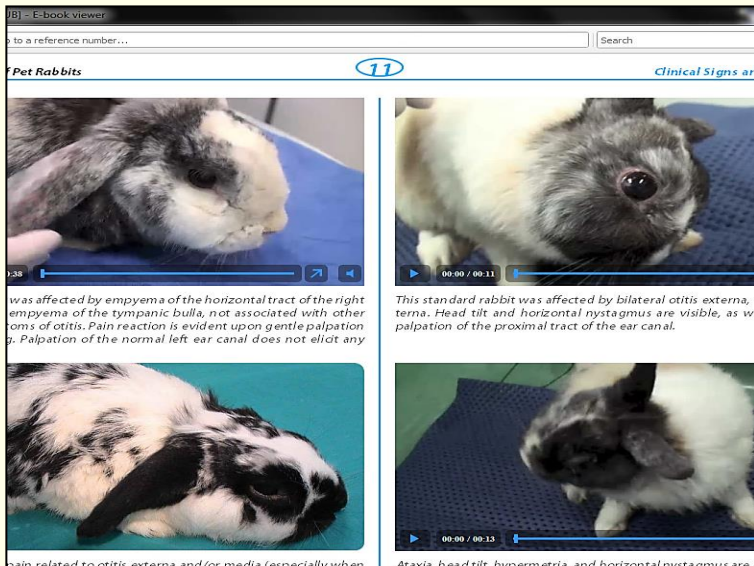
Photographs for a paper book must have an educational message or be aesthetically interesting. A good picture should never shock, it should never convey a value of horror.

Selected photographs must have a good quality for reproduction in a book or a journal.



Screen-print from “Skin Diseases of Rabbits”, by E. van Praag et al., 2010

E-books can include high quality video demonstrations of clinical or surgical topics. They should be 2-3 minutes long. It is usually accompanied a 25-50 word legend or audio voice-over.



Screen-print from “Ear Surgery of Pet Rabbits”, by V. Capello et al., 2015

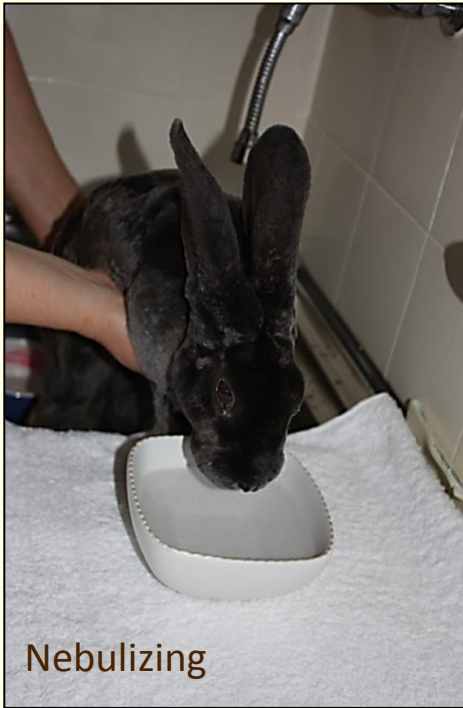

Care sheets for owners

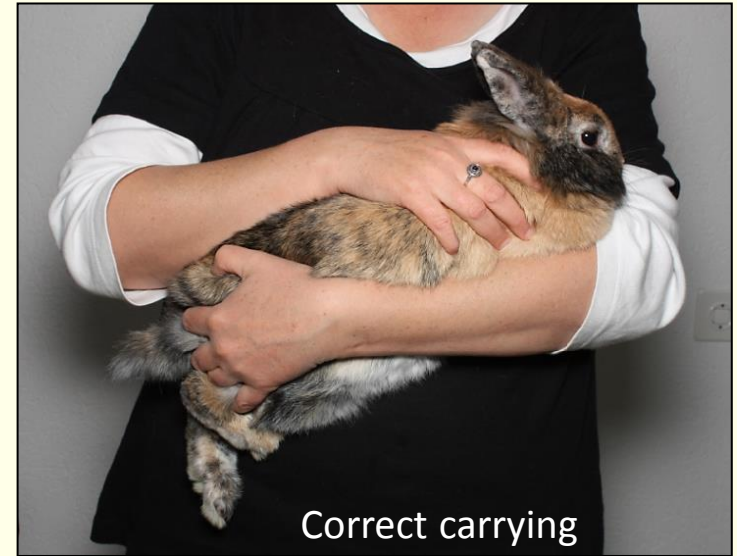
Tips on husbandry, feeding, carrying, transportation, care, etc...

Pictures are worth thousands words !!!

This is particularly the case when preparing care sheets for owner of exotic and unusual pets.




Nebulizing



Correct carrying



Weighing



Washing bottom after diarrhea

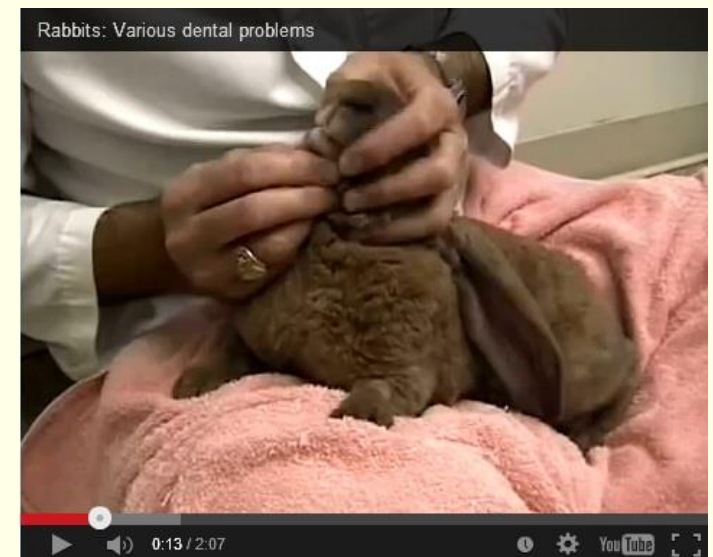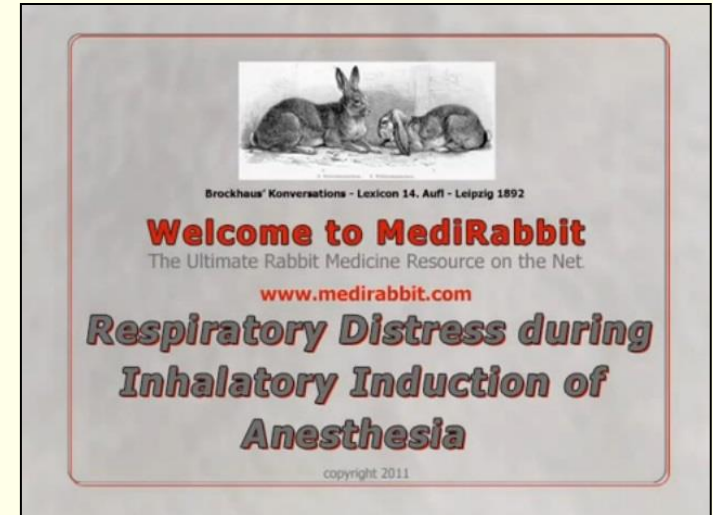


Producing educative video's

Video production is playing an increasingly important role in veterinary medicine.

Collaboration with a video producer in order to produce high quality medical video's for use in healthcare in animals: teach veterinarians and students or inform the owners of sick animals.

Since a few years, medical photographers are also responsible for the management of audio-visual services for veterinary video conferences, e.g., video conferencing from operating rooms.



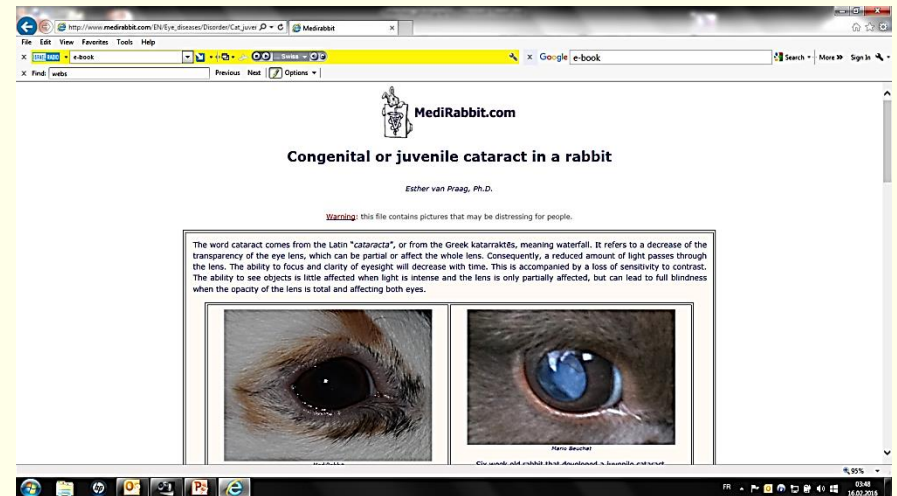
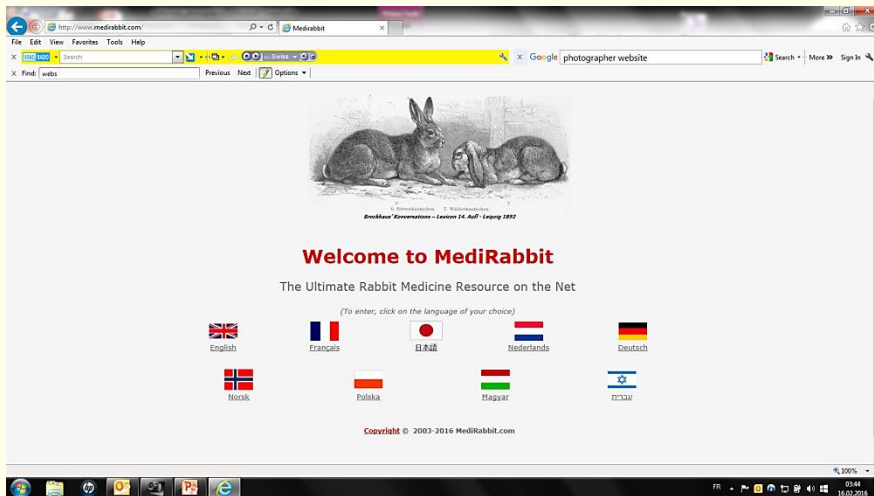


Websites

Better information. Better health.

A library of photographs is also very useful for the design of websites about animals and diseases.

These provide health information, picture of the characteristics of a disease, demonstrate a procedure or treatment and give tools and services for both pet owners and pet health professionals/veterinarians.





Biggest reward after a photo session



Acknowledgement

Thank you to Arie van Praag, Akira Yamanouchi, Dr Amir Maurer, Michel Gruaz, Shannon for the permission to use their pictures.

Thank you also to all the rabbit that so patiently allowed to be restrained and photographed, sometimes under challenging conditions.



Thank you